

Analysis of Pharyngeal Swallowing in Healthy Subjects

Naohiko SUMIYA and Akira ISHIDA

Department of Rehabilitation Medicine, Tokai University School of Medicine

(Received October 30, 2000; Accepted January 12, 2001)

The Biomechanics of pharyngeal swallowing was investigated by videofluorography in 10 healthy subjects (9 men and 1 woman) during swallowing of 3ml of fluid contrast medium and a small spoonful of jelly contrast medium.

The items measured were the sequential movement of the hyoid bone: hyoid bone angle; epiglottis angle; antero-posterior diameters of the thyroid cartilage, larynx, hypopharynx, and pharyngoesophageal junction; and transport time of the swallowed bolus.

It was concluded that the movement of the hyoid bone and thyroid cartilage and the angle of the epiglottis were important for evaluation of pharyngeal swallowing, and that the antero-posterior and vertical movement of the hyoid bone showed a significant relationship to transport time of the swallowed bolus as far as the esophagus, which was within 400 msec on average.

Key words : Videofluorography, Pharyngeal swallowing, Bolus transit time, Hyoid bone, epiglottis

INTRODUCTION

The physiology of swallowing has been investigated by radiography [1] and the measurement of intrapharyngeal and intraesophageal pressure [2]. More recently, videofluorography has been widely applied for the diagnosis of dysphagia.

Swallowing can be subdivided into an initial oral phase and a subsequent pharyngeal phase. While the oral phase is largely voluntary and highly variable, depending upon several conditions, the pharyngeal phase is a complex motor event which is highly controlled by subtle innervation and which is accomplished within an extremely short time.

These characteristics have rendered the precise biomechanical evaluation of pharyngeal swallowing difficult.

Bosma *et al.* [3] presented a detailed neurological study of neural and muscular activity in pharyngeal swallowing. Saunders *et al.* [4] revealed the mechanism of deglutition by cineradiography, and other authors have investigated movement in swallowing by motion analysis of the hyoid bone and larynx [5-11].

Disturbance of pharyngeal swallowing

has been understood as a derangement of deglutition, the innervation of which is complex. To date, however, there has been no demonstration of the motion pattern of organs and tissues involved in swallowing, particularly with regard to possible differences based on bolus type.

The aim of the present study was to measure the movement of organs and tissues which participate in pharyngeal swallowing.

We also wanted to clarify interrelationships among the loci of movement and angles of organs and tissues and to determine the passage time of the swallowed bolus in the pharyngeal phase.

SUBJECTS AND METHODS

1. Subjects

The subjects consisted of 10 healthy adults (9 males, 1 female; age 32 to 45 years, mean 33.4 years) who had no abnormality in swallowing or of the pharynx and larynx.

They were informed of the purpose of the study and procedures involved and agreed to participate in the study.

2. Methods of study

The subjects underwent videofluoroscopy standing upright.

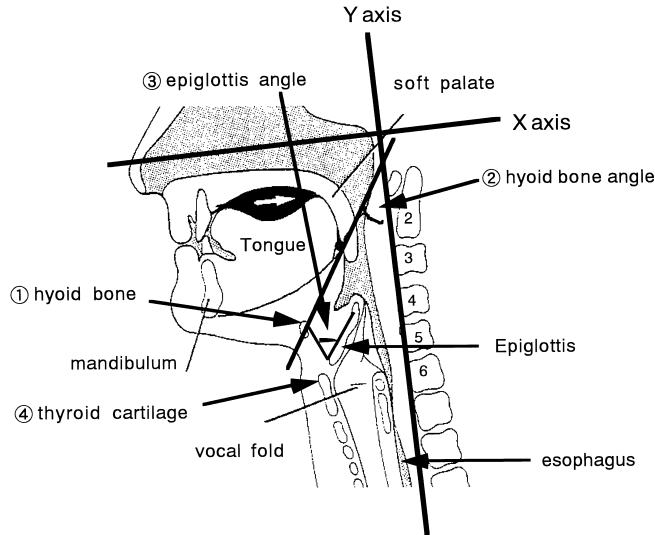


Fig. 1 Radiograph of the larynx and pharynx

Radiofluorographs of the head and neck were taken both from the lateral and frontal directions. Videofluoroscopes were recorded with a videotape recorder (VTR, Sony VO-9850, Tokyo) connected to a radiographic machine. Two kinds of bolus were used for each examination; gastrographine-Æ in liquid form (3 ml) in one trial and gastrographine-Æ jelly (medium-sized spoonful, approximately 10 g) in the second. Each was swallowed 3 times in each examination.

Radiography was taken at 67 to 70 Kv and 1 mA.

The VTR image was directly measured on a monitor after the stationary image of one frame (30 frames/sec) was input in a locus measurement apparatus (For-a video measuring, FORA IV-560 Tokyo).

The aspect ratio of the VTR image was corrected at the ratio of 1:1. Analysis of pharyngeal swallowing was based on measurement of every 1st frame from the point when the first part of the swallowed bolus arrived at the level of the superoanterior aspect of the third cervical vertebra (0 frame) until the last part of the bolus had completely passed the pharyngoesophageal junction, indicated as the midpoint between the fifth and sixth cervical vertebrae.

The movement of organs that participate in swallowing was measured as hyoid bone movement, hyoid bone angle, epiglottis angle, and anteroposterior diameters of the

thyroid cartilage, larynx, hypopharynx and pharyngoesophageal junction.

Measurements are shown schematically in Fig. 1. In accordance with Nakahara's method [9], the Y axis (standard line, vertical direction) was defined as a line through the superoanterior edge of the third cervical spine and inferoanterior edge of the fifth cervical spine in the lateral view. The X axis (anteroposterior direction) was defined as a line perpendicular to the Y axis.

Movement distance was calculated for both directions.

The parameters calculated were as follows: (1) Hyoid bone excursion (A, inferior edge; B, superior edge; X axis, horizontal; Y axis, vertical); (2) hyoid bone angle, the angle constructed by line AB and the Y axis; (3) epiglottis angle, angle where the line connecting the tip of the epiglottis and the middle point of the median thyrohyoideum ligament intersected the hyoid bone upper line; (4) traveled distance of the tip of the thyroid cartilage defined with a marker, measured in both the X and Y axis directions; Transit time of the swallowed bolus was measured for the following 3 intervals from the superoanterior edge of the third cervical spine to the pharyngoesophageal junction: (5) arrival time of the first part of the swallowed bolus; (6) disappearance time of the last part of the bolus; and (7) passage time through the pharyngoesophageal junction

of the bolus.

3. Data analysis

Excursion distances of the organs and swallowed bolus were measured as a static image on every frame sequentially from 0 to 533 msec, and the locus of movement of organs was represented by absolute distance.

The 226 items measured were subject to locus analysis using the Mann-Whitney test and Spearman's rank correlation coefficient.

RESULTS

Figure 2a and b shows the excursion locus of the hyoid bone for both the X (horizontal) and Y (vertical) axes.

I) Excursion locus of point A (inferior edge) of the hyoid bone.

The hyoid bone started to move anteriorly (X axis) and showed a characteristic locus of movement. Maximum anterior movement of A was 7.6 ± 11.9 mm for the liquid bolus at 400 msec and 7.4 ± 19.8 mm for the solid bolus at 267 msec, after which posterior movement occurred. Maximum superior movement was 11.6 ± 4.7 mm for the liquid bolus at 133 msec and 10.0 ± 12.3 mm for the solid bolus at 400 msec. In contrast, superior movement for the solid bolus showed little change from 0 to 133 msec but then moved to the maximal position.

II) Excursion locus of point B (superior edge) of the hyoid bone.

Point B of the hyoid bone moved anteriorly to the maximum position of 7.9 ± 12.3 mm for the liquid bolus at 400 msec and of 6.7 ± 18.9 mm for the solid bolus at 267 msec, and thereafter returned to the resting (non-active) positions. The superior maximum position was 9.9 ± 3.0 mm for the liquid bolus at 167 msec and 7.5 ± 6.6 mm for the solid bolus at 67 msec. Thus, the excursion locus of the hyoid bone, as measured for points A and B, differed according to the type of bolus swallowed. Time to maximal position also differed according to excursion direction (anterior and superior) and excursion time depending on bolus type, except for excursion time with the solid bolus, which was the same for points A and B. Absolute distance of hyoid bone excursion during swallowing did not significantly differ by bolus type.

III) Locus of anteroposterior movement of the hyoid bone (X axis).

Movement of points A and B of the hyoid bone during swallowing was divided into 3 phases, as follows:

- 1) an anterior motion phase, which consisted of an initial rapid forward movement followed by a gradual movement to the maximal point;
- 2) a stationary phase during which the hyoid bone did not move significantly; and
- 3) a posterior phase during which the hyoid bone returned to the position it occupied before the start of swallowing.

The excursion locus of points A and B was approximately the same for the liquid and solid boluses.

IV) Locus of superoinferior movement of the hyoid bone (Y axis).

Compared to movement on the X axis, distance traveled in Y axis movement was smaller and the time of elevation was shorter.

On frames after 333 msec, corresponding to the posterior motion phase, however, movement patterns for the liquid and solid boluses were different.

For the liquid bolus, movement occurred in 4 phases:

- 1) elevation, showing initial elevation;
- 2) stationary;
- 3) rapid descent; and;
- 4) slow descent.

For the solid bolus, movement occurred in 5 phases:

- 1) elevation;
- 2) stationary;
- 3) short descent;
- 4) re-elevation, showing rapid and significant elevation; and
- 5) rapid descent.

Thus, the superoinferior movement of the hyoid bone showed a characteristic difference during swallowing between the liquid and solid boluses.

Figure 3 depicts sequential changes in the angles of the hyoid bone and epiglottis during swallowing of liquid and solid boluses.

Hyoid bone angle just before the start of swallowing was 42.6 ± 8.7 degrees for the liquid bolus and 44.5 ± 10.2 degrees for the solid bolus, showing no statistical difference.

After swallowing began, the angle slightly increased to 45.3 ± 20.8 degrees on 0 msec, indicating a horizontal decline.

On 33 msec to 300 msec, the angle increased to 52.4 ± 14.7 degrees. Maximal angle was 56.6 ± 14.2 degrees on 100 msec

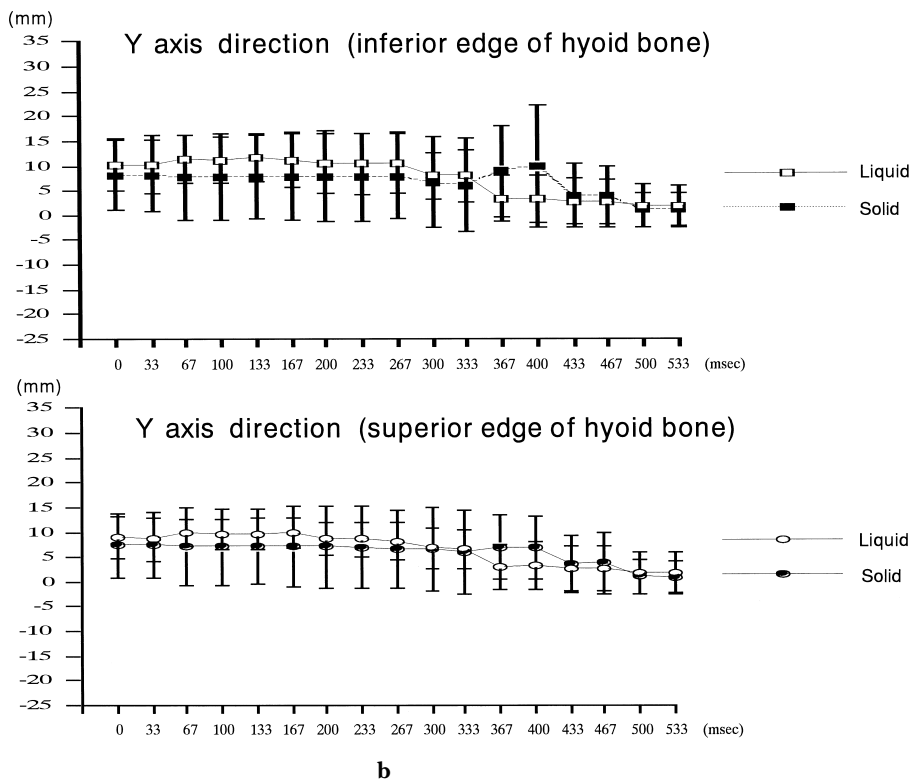
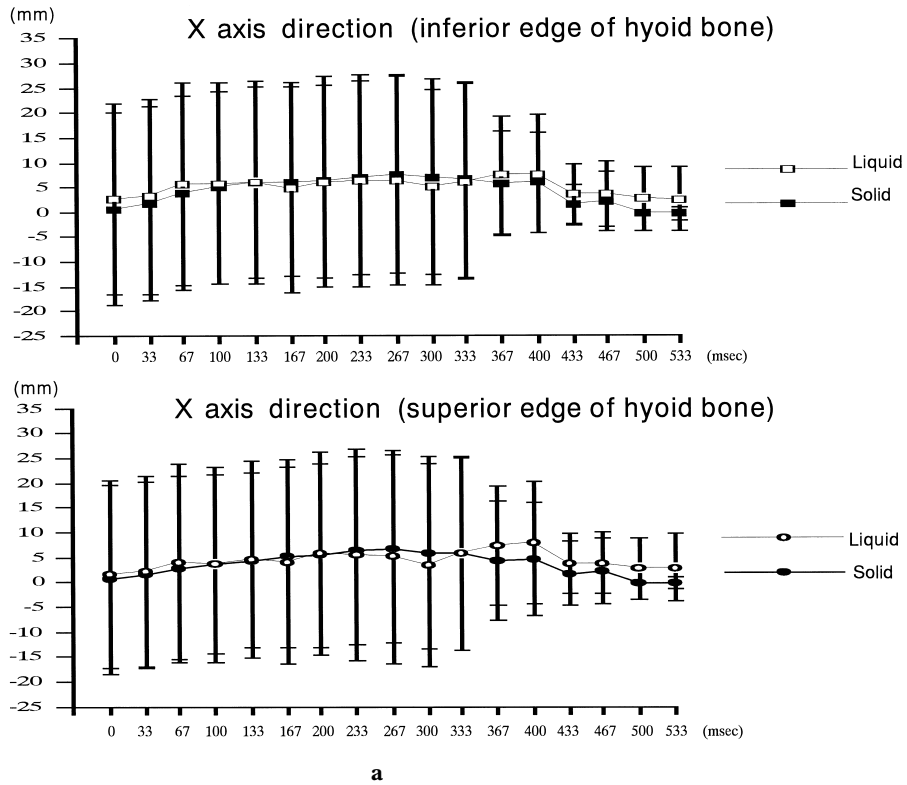


Fig. 2a, b Excursion locus of the hyoid bone.

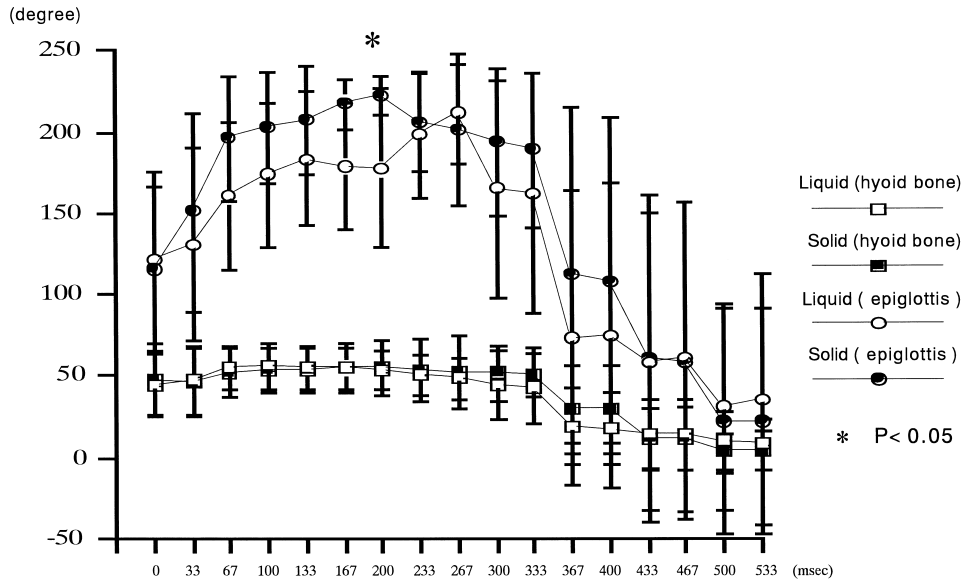


Fig. 3 Locus of changes in hyoid bone and epiglottis angles

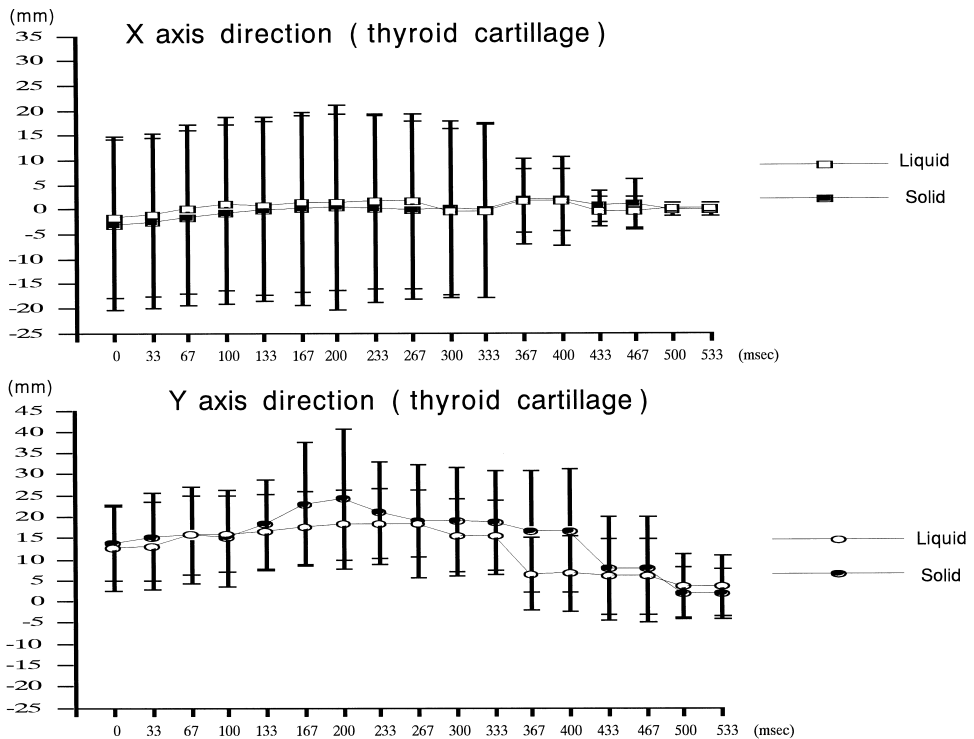


Fig. 4 Excursion locus of the thyroid cartilage

for the liquid bolus and 55.4 ± 17.1 on 200 msec for solid bolus.

After the 333 msec, the hyoid bone angle decreased to bring the hyoid bone more vertical and on 500 msec reached 29.4 ± 27.0

degrees, which was more vertical than before the start of swallowing.

There was no significant difference in hyoid bone angle between the liquid and solid boluses.

The backward reclining angle of the epiglottis changed more during swallowing than that of the hyoid bone angle, and strongly participated in closure of the larynx.

Mean angle of the epiglottis in the resting state was 102.1 ± 17.2 degrees for both the liquid and solid boluses.

At 0 msec, it became 120.9 ± 54.9 degrees, indicating a rapid backward recline of the angle and the start of epiglottis closure.

The epiglottis angle changed during swallowing in a bolus-dependent manner, with a statistically significant difference between the liquid and solid boluses at 200 msec.

Maximum epiglottis angle was 211.4 ± 30.7 degrees at 267 msec for the liquid bolus and 222.2 ± 11.8 degrees at 200 msec for the solid bolus. After 267 msec, the epiglottis started to decline forward and the angle decreased, rapidly returning to its position before swallowing after 333 msec.

The traveled locus of the thyroid cartilage is shown in Fig. 4.

For a liquid bolus, the locus was divided into 3 phases in the anteroposterior direction: 1) forward motion, 2) stationary, and 3) backward motion. In the superoinferior direction, it was divided into 4 phases: 1) elevation, 2) descent, 3) stationary, and 4) recovery.

In contrast, the excursion locus during swallowing of the solid bolus consisted of 4 phases in the anteroposterior direction: 1) forward motion, 2) backward motion, 3) stationary, and 4) forward motion.

In the superoinferior direction, likewise, the locus was divided into 4 phases as with the liquid bolus, and maximum elevation was obtained at 200 msec. The recovery phase was rapidly completed on swallowing the liquid bolus, but was considerably prolonged with the solid bolus. Thus, the excursion locus of the thyroid cartilage was bolus-dependent. Further, the absolute distance of movement of the thyroid cartilage was greater in the superoinferior direction than in the anteroposterior direction. Maximum elevation distance was 18.1 ± 8.3 mm at 200 msec for the liquid bolus and 24.3 ± 16.5 mm at 200 msec for the solid, showing no statistically significant difference.

The time for maximal elevation of the thyroid cartilage coincided with the time required for maximal backward recline of

the epiglottis.

Table 1 shows transport times of the swallowed bolus from the level of the upper edge of the 3rd cervical vertebra to the pharyngoesophageal junction. There was no significant difference in transfer time between the liquid and solid boluses. Arrival time of the first part of the bolus at the pharyngoesophageal junction was 38 msec shorter for the solid than for the liquid bolus.

On the contrary, transit time through the pharyngoesophageal junction was 34 msec shorter for the liquid than for the solid bolus.

It would be reasonable to divide bolus transport time into 1) transit time from the fornix to the pharyngoesophageal junction and 2) passage time through the pharyngoesophageal junction.

Swallowing was completed within 400 msec on average, irrespective of bolus. Most of the time taken for swallowing was spent in passage through the pharyngoesophageal junction.

DISCUSSION

Pharyngeal swallowing is a complex action involving neurophysiological function and systematically controlled muscle activity, and is completed in a short time. Swallowing is reported [4, 15, 16] to involve the following steps: 1) laryngeal elevation, 2) backward and downward recline of the epiglottis (forward and upward elevation of the hyoid bone and fornix) and closure of the upper part of the glottis (forward and upward shift of the larynx), 3) forward and upward movement of the larynx (after elevation of the epiglottis, further elevation of the larynx, contraction of the glottis obturator muscle and relaxation of the cricopharyngeal muscle), 4) complete larynx closure, 5) maximum elevation of the root of the tongue and the larynx and peristalsis of the fornix on arrival of the first part of the swallowed bolus at the pharyngoesophageal junction, 6) decline of the larynx, and 7) return of the epiglottis (former position) and subsequent contraction of the cricopharyngeal muscle.

Despite the importance of this pattern of swallowing to our understanding of pharyngeal swallowing, no method of rehabilitation of swallowing dysfunction based on this pattern has been developed.

Electromyographically, pharyngeal swal-

Table 1 Transport time of swallowed bolus

| | arrival of first part of bolus | passing of last part of bolus | passage through the pharyngeoesophageal junction |
|--------|--------------------------------|-------------------------------|--|
| liquid | 146.7 ± 108.3* | 399.7 ± 107.5 | 253.0 ± 66.0 |
| solid | 108.9 ± 41.3 | 396.0 ± 64.1 | 287.1 ± 46.8 |

*All Measurements of time presented AS (msec).

Table 2 Correlation coefficients of transit time of bolus (movement of the hyoid bone)

| | liquid | | solid | |
|--------------|----------------------|--|----------------------|--|
| | passing of last part | passage through pharyngeoesophageal junction | passing of last part | passage through pharyngeoesophageal junction |
| AX (433msec) | 0.821* | 0.333 | 0.176 | 0.315 |
| AX (467msec) | 0.821* | 0.333 | 0.176 | 0.315 |
| AY (367msec) | 0.883* | 0.342 | 0.870* | 0.624 |
| AY (400msec) | 0.883* | 0.342 | 0.885** | 0.579 |
| AY (433msec) | 0.821* | 0.333 | 0.758* | 0.861* |
| AY (467msec) | 0.821* | 0.333 | 0.697 | 0.824* |
| BX (433msec) | 0.821* | 0.333 | 0.176 | 0.315 |
| BX (467msec) | 0.821* | 0.333 | 0.176 | 0.315 |
| BY (367msec) | 0.883* | 0.342 | 0.815* | 0.521 |
| BY (400msec) | 0.883* | 0.342 | 0.815* | 0.521 |
| BY (433msec) | 0.821* | 0.333 | 0.745 | 0.842* |
| BY (467msec) | 0.821* | 0.333 | 0.661 | 0.824* |

Spearman's rank correlation coefficient *P<0.05 **P<0.01

lowing coincides with the period of relaxation of the cricopharyngeal muscle, at which time the hyoid bone starts to elevate [9, 15].

We investigated the mechanism of swallowing by videofluorography in healthy subjects. The movement of organs participating in pharyngeal swallowing and the changes of organ angle and transport time of the swallowed bolus were measured and their interrelationships evaluated by multifactorial analysis.

1. Transport time of the swallowed bolus.

Total transport time of the bolus was approximately the same irrespective of the

kind of bolus (liquid or solid), at about 400 msec on average.

However, when time intervals for passage from the fornix to the pharyngoesophageal junction were subdivided, considerable differences in passage time were seen. For example, passage through the junction was prolonged. This subdivision in transport time also depended on the kind of bolus swallowed. To the best of our knowledge there have been no previous reports concerning subdivisions in transport time.

Transport time through the pharyngoesophageal junction was longer compared with that through other parts.

Table 2 shows the relation between trans-

port time of the bolus until it reached the esophagus and swallowing patterns, estimated by Spearman's rank correlation coefficient.

Hyoid bone movement showed a close relationship with transport time of the last part of the bolus and esophageal transport time.

Transport time of the last part of a liquid bolus showed a positive correlation ($p < 0.05$) with backward and downward movement of the hyoid bone. Transport time of a solid bolus had significant positive correlations ($p < 0.05$, $p < 0.01$) with elevations in stationary movement and re-elevation of the hyoid bone.

Also, with a solid bolus, there was a significant correlation ($p < 0.05$) with downward movement of the hyoid bone.

2. Pattern recognition of hyoid bone movement.

Motion pattern of the hyoid bone during swallowing was divided into 3 phases in the anteroposterior direction for both kinds of boluses, into an upward-downward direction of 4 phases for the liquid bolus and 5 phases for the solid.

Nakahara *et al.* [9] divided the pattern into 4 phases in the anteroposterior direction and 5 phases in the upward-downward direction for the liquid bolus. However, their classification is considered fundamentally similar to ours, although in somewhat greater detail.

The pattern of hyoid bone movement for the solid bolus was characterized by an initial anterior-superior motion of the hyoid bone, which led to early dilatation of the pharyngoesophageal junction.

From these correlations of movement, a precise time component and a swallowed bolus transport time were determined.

3. Relation between hyoid bone angle and epiglottis angle.

It has been reported that the hyoid bone angle in the resting state is 24 to 30 degrees, and that the angle becomes larger (horizontal position) following the completion of swallowing than in the resting state.

In the present study, the hyoid bone angle in the resting state was 42.6 degrees, which was larger than the value reported above.

Relatively constant values (52.4 ± 14.7

degrees) were maintained for about 330 msec thereafter and then decreased irrespective of the kind of bolus. After completion of swallowing, the angle was more decreased than in the resting state.

This means that the suprahyoid muscle and infrahyoid muscle connected to the hyoid bone body performed the swallowing motion in good balance, and the anteroposterior movement of the hyoid bone functioned effectively at the beginning of swallowing.

The epiglottis angle tended to show a wider range in the backward reclining angle compared to the hyoid bone.

The epiglottis angle was 102.7 degrees on average in the resting state and increased in a nonbolus-dependent fashion.

A significant difference in angle between the liquid and solid boluses was observed at 200 msec, with the backward reclining angle markedly increased with the solid bolus.

The time of maximal reclining angle was delayed during liquid bolus swallowing, with a time lag of 67 msec.

This time lag was related to the arrival time of the swallowed bolus, and the time difference of about 37.8 msec in backward reclining angle between the solid and liquid boluses was considered due to difference in mass.

4. Movement of the thyroid cartilage.

Movement of thyroid cartilage was classified by Furukawa [11] and Nakahara [9] into 5 phases for the superoinferior direction, and into 2 phases for the anteroposterior direction, by measurement of pharyngeal swallowing according to movement of the thyroid cartilage.

In the present study, the upward-downward direction was divided into 4 phases (elevation, descent, stationary, and recovery) and the anteroposterior direction into 3 phases (forward motion, stationary, and backward motion) for the liquid bolus and into 4 phases (forward motion, backward motion, stationary, and forward motion) for the solid bolus.

Vertical movement of the thyroid cartilage showed a rapid elevation at 200 msec for the solid bolus compared to the liquid bolus, coinciding with the timing of the maximal angle of the backward decline of the epiglottis.

This finding indicates the role of the epiglottis in complete closure as safety for the larynx.

Since hyoid bone movement is related to thyroid cartilage movement, although indirectly, evaluation of the muscles involved in hyoid movement may be a key to rehabilitation of swallowing disturbances.

Movement of the hyoid bone, epiglottis angle, and movement of the thyroid cartilage were important factors for evaluation of pharyngeal swallowing.

It is also important that the time sequence of swallowing was dependent on the kind of swallowed bolus.

Rapid descent of the hyoid bone, forward declining motion of the epiglottis, and descent of the thyroid cartilage occurred at 400 to 467 msec for the liquid bolus.

In contrast, for the solid bolus, the main pattern of movement was vertical motion of the hyoid bone and thyroid cartilage movement of frames from 133 to 400 msec.

These findings indicate that since transit time of the pharyngoesophageal junction is a key point for evaluation of the mechanism of swallowing, observation of this area is important for the treatment of dysphagia.

The hyoid bone, epiglottis, and thyroid cartilage are the most important organs for starting swallowing, and cooperation among them leads to smooth action in swallowing.

An understanding of these mechanisms of swallowing is important for effective rehabilitation of dysphagia.

REFERENCES

- 1) Ramsey GH, Watson JS, Gramiak R, Weinberg SA: Cinefluorographic analysis of the mechanism of swallowing. *Radiology* 64: 498-518, 1955.
- 2) Olsson R, Nilsson H, Ekberg O: Simultaneous videoradiography and pharyngeal solid state manometry (videomanometry) in 25 nondysphagic volunteers. *Dysphagia* 10: 36-41, 1995.
- 3) Bosma JF, Martin MW, Donner, Tanaka E, Robertson D: Anatomy of the pharynx, pertinent to swallowing. *Dysphagia* 1: 23-33, 1986.
- 4) Saunders JB, Davis C, Miller ER: The mechanism of deglutition (second stage) as revealed by cine-radiography. *Ann Otol Rhinol Laryngol* 69: 897-918, 1951.
- 5) Tanaka E, Palmer JB, Siebens A, Baltimore: Motions of the posterior pharyngeal wall in swallowing. *Laryngoscope* 98: 414-417, 1988.
- 6) Kahrilas PJ, Logemann JA, Gibbons P: Food intake by maneuver: An extreme compensation for impaired swallowing. *Dysphagia* 7: 155-159, 1992.
- 7) Welch MV, Logemann MJ, Rademaker AW, Kahrilas PJ: Changes in pharyngeal dimensions effected by chin tuck. *Arch Phys Med Rehabil* 74: 178-181, 1993.
- 8) Crary MA, Butler MK, Baldwin BO: Objective distance measurements from videofluorographic swallow studies using computer interactive analysis: Technical note. *Dysphagia* 9: 116-119, 1994.
- 9) Nakahara M: A cinefluorographic study of hyoid and laryngeal movements during deglutition. *Journal of Otolaryngology of Japan* 90: 669-679, 1987.
- 10) Kaneko I: A cinefluorographic study of hyoid bone movement during deglutition. *Journal of Otolaryngology of Japan* 95: 974-984, 1992.
- 11) Furukawa K: Cineradiographic analysis of laryngeal movement during deglutition. *Journal of Otolaryngology of Japan* 87: 169-181, 1984.
- 12) Sumiya N, Ishida A, Toyokura M, Tanaka H, Uchiyama K, Kenichi M: Rehabilitation of pharyngeal dysphagia intermittent air-stretching method with balloon catheter. *Sogo Rehabilitation* 20: 513-516, 1992 (in Japanese).
- 13) Hesaka H: Measurement of the swallowing pressure curve in normal adult. *Oto-Rhino-Laryngology* 34: 395-410, 1991 (in Japanese).
- 14) Hirano M: Pharyngeal stage of swallowing - its physiology and pathologies. *Jpn. Bronchoesophagol Soc.* 31(1): 1-9, 1980 (in Japanese).
- 15) Kahrilas PJ, Logemann JA: Volume accommodation during swallowing. *Dysphagia* 8: 259-265, 1993.
- 16) Shin T: Closure of the larynx during the swallowing. *J. Jpn. Bronchoesophagol Soc.* 26(3): 131-142, 1975 (in Japanese).