

Effect of pouched reconstruction after total gastrectomy on ERCP and ENBD

— REPORT OF TWO CASES —

Takafumi SEKKA, Yasumasa KONDOH, Jun AOKI,
Yasuo OHTANI* and Hiroyasu MAKUUCHI*

*Tokai University Tokyo Hospital
Department of Surgery, Tokai University School of Medicine

(Received March 10, 2004; Accepted July 30, 2004)

Endoscopic retrograde cholangiopancreatography (ERCP) and endoscopic nasobiliary drainage (ENBD) are well known to be useful but these procedures are rarely indicated in patients after total gastrectomy, because the endoscopic approach is more difficult in the patients with standard reconstructions such as Roux-en-y esophagojejunostomy after total gastrectomy.

Gastric replacement with various enteric reservoirs after gastrectomy has been used to improve the postprandial symptoms and nutrition of patients after total gastrectomy. We have been performing jejunal pouch double tract reconstruction (JPD) after gastrectomy and the patients' postoperative course has been satisfactory. In this report, we describe two cases of biliary tract disorders after total gastrectomy. One was choledocholithiasis and the other was bile leakage after cholecystectomy. In each case, we performed ERCP, and treated with ENBD tube placement, and we obtained satisfactory results.

We emphasize that ERCP and ENBD are also useful and easy procedures for biliary tract disease in postgastrectomy patients with JPD reconstruction as well as in patients who have not undergone intestinal reconstruction. The advantages of JPD reconstruction are not only improving the postprandial symptoms and the nutrition of patients after total gastrectomy, but that it provides an easy endoscopic approach to the papilla of Vater.

Key words : Total gastrectomy, ERCP, ENBD

INTRODUCTION

Endoscopic retrograde cholangiopancreatography (ERCP) and endoscopic nasobiliary drainage (ENBD) are well known to be useful endoscopic procedures for biliary tract disease [1, 2]. But, these procedures are uncommonly indicated in patients after total gastrectomy, because the endoscopic approach to the papilla of Vater and placement of drainage tubes are considered more difficult in the patients with standard reconstructions such as Roux-en-y esophagojejunostomy after total gastrectomy [3, 4].

Gastric replacement with various enteric

reservoirs after gastrectomy has been used to improve the postprandial symptoms and nutrition of patients after total gastrectomy [5]. Since 1991 we have performed jejunal pouch double tract reconstruction (JPD) after gastrectomy and the patients' postoperative course has been satisfactory [6, 7].

In this report, we describe two cases of biliary tract disorders after total gastrectomy. One was a patient with choledocholithiasis and the other was a patient with bile leakage after cholecystectomy due to acute emphysematous cholecystitis. In each case, we performed ERCP, and treated with ENBD tube placement, and we obtained satisfactory

results.

We emphasize that ERCP and ENBD are as useful and easy procedures for biliary tract disease in postgastrectomy patients with jejunal pouch double tract reconstruction as in patients who have not undergone intestinal reconstruction. The advantages of jejunal pouch double tract reconstruction are not only improving the postprandial symptoms and the nutrition of patients after total gastrectomy, but providing an easy endoscopic approach to the papilla of Vater.

CASE REPORTS

Case 1

An 80-year-old man was admitted to our hospital complaining right hypochondrial pain, fever, and jaundice. The result of the blood tests were as follows: Hb, 11.2 g/dl (normal: 14-18 g/dl); white blood cell count 5000/ μ l (normal: 4000-8000/ μ l); total bilirubin, 3.7 mg/dl (normal: 0.2-1.2 mg/dl); GOT, 73 IU/l (normal: 8-40 IU/l); GPT, 51 IU/l (normal: 5-35 IU/l) alkaline phosphatase 210 IU/l (normal: 70-230 IU/l). This patient had a history of glaucoma and gastric cancer. He had undergone total gastrectomy with JPD reconstruction for the gastric cancer. Abdominal computed tomography and

ultrasonography revealed dilatation of the intra-hepatic bile duct and the common bile duct (CBD). Gallbladder stones, choledocholithiasis, and acute obstructive cholangitis were suspected. ERCP revealed multiple bile duct stones. We placed an ENBD tube for the biliary drainage (Fig. 1). Three days after the drainage, cholecystectomy with choledochotomy was carried out. The common bile duct was primarily closed with the nasobiliary drainage tube placement. The NBD tube was removed on the 5th postoperative day. The patient was discharged on the 15th postoperative day.

Case 2

A 50-year-old man was admitted to our hospital complaining of right hypochondrial pain and fever. The results of the blood tests were as follows: Hb, 13.2 g/dl (normal: 14-18 g/dl); white blood cell count 15600/ μ l (normal: 4000-8000/ μ l); total bilirubin, 1.3 mg/dl (normal: 0.2-1.2 mg/dl); GOT, 39 IU/l (normal: 8-40 IU/l); GPT, 34 IU/l (normal: 5-35 IU/l) alkaline phosphatase 155 IU/l (normal: 70-230 IU/l). His medical history included total gastrectomy with JPD reconstruction for gastric cancer. An abdominal X-ray and computed tomography revealed

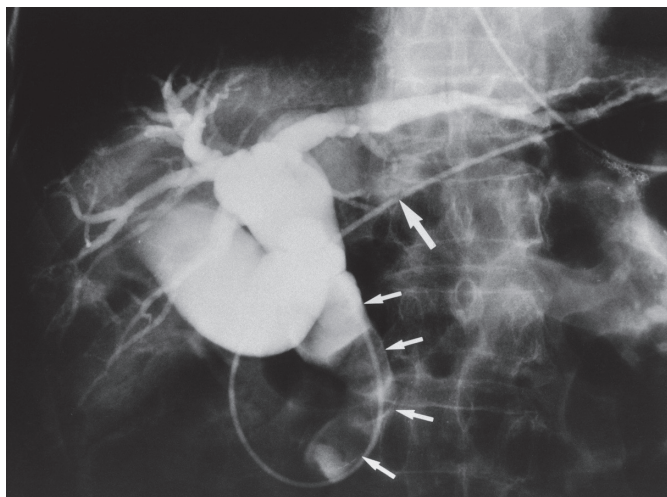


Fig. 1 Cholangiography via a nasobiliary drainage tube demonstrates a dilated biliary tree and multiple filling defects in CBD for choledocholithiasis (small arrows). The large arrow indicates inserted ENBD tube.

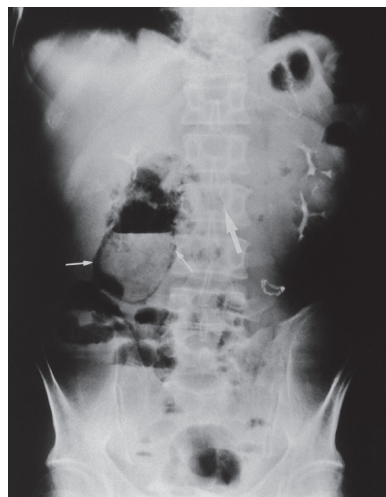


Fig. 2 Plain abdominal X-ray film demonstrating gas forming in the gallbladder wall and lumen (small arrows). The large arrow is pointing to the stapler of duodenojejunosomy in jejunal pouch double tract reconstruction.

air in the gallbladder wall and its lumen (Fig. 2), diagnosis of acute emphysematous cholecystitis was made, and cholecystectomy was carried out. The gallbladder wall showed gangrenous change from the fundus to the neck. The cystic duct could not be clearly identified during the operation but the necrotic cystic duct was tied and drainage tube was placed at the subhepatic space. Bile discharge from the drainage tube was noted 8 days after cholecystectomy and the ERCP was performed. Cholangiography revealed contrast medium leakage from the stump of the cystic duct. An ENBD tube was placed (Fig. 3), and bile leakage decreased and resolved after drainage. He discharged on the 24th postoperative day.

DISCUSSION

Pancreatobiliary disorders are not rare in postgastrectomy patients, and the incidence of biliary tract lithiasis is higher in the patients after gastrectomy than in those without gastrectomy [8]. ERCP is an established modality for the diagnosis and treatment of pancreatobiliary disorders. But there are a number of problems with ERCP in patients with Billroth II or Roux-en-Y reconstruction. It is difficult to reach the papilla of

Vater by intubating the long afferent loop. Cannulation and endoscopic therapy from a reverse position is also difficult.

Experienced biliary endoscopists have reported the performance of ERCP in postgastrectomy patients. Hintze *et al.* reviewed their experience with 2257 ERCPs. All patients had undergone gastrointestinal reconstruction in the form of gastrojejunostomy by either Billroth II anastomosis or Roux-en-Y reconstruction. Thirty patients (46 %) underwent Billroth II reconstruction with Braun enteroenterostomy, 29 (45 %) underwent Billroth II anastomosis, and the remaining 6 patients (6 %) had Roux-en-y gastrojejunostomies. The most common indication for ERCP in the patients who underwent gastrojejunostomy was choledocholithiasis (64 %), follow by papillary stenosis (17 %), tumor obstruction (12 %), and duodenal diverticulum associated with papillary dysfunction (7 %). In the Roux-en-y patients, the indications were equally divided among bile duct stones, papillary stenosis, and tumor obstruction. Access to the duodenal stump was only successfully achieved in a third of the patients (two of six) with Roux-en-Y reconstruction and the failures were related to long afferent segments [3]. Naoyuki

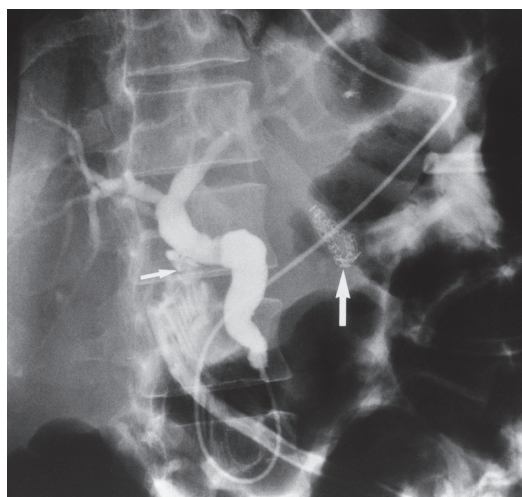


Fig. 3 Cholangiography via a nasobiliary drainage tube shows the contrast medium leakage from the cystic duct stump (small arrow). The large arrow is pointing to the stapler of duodenojejunosomy in jejunal pouch double tract reconstruction

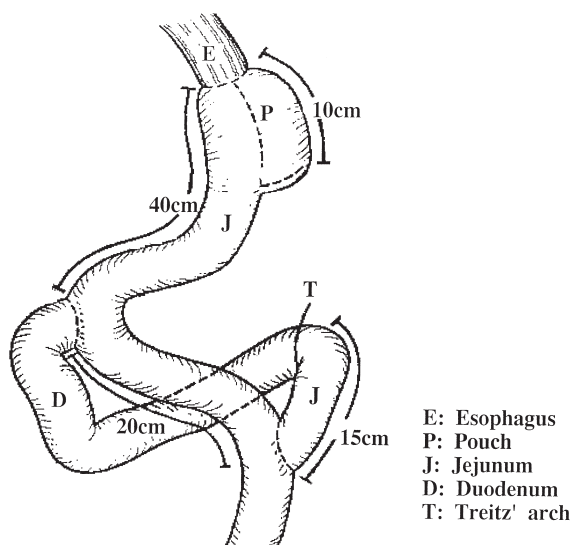


Fig. 4 Schematic representation of jejunal pouch double tract reconstruction

E: Esophagus
P: Pouch
J: Jejunum
D: Duodenum
T: Treitz' arch

Furuya *et al.* reviewed their experience with 164 ERCPs in 118 consecutive patients with Billroth II reconstruction performed over an 8-year period. Standard or therapeutic duodenoscopes (JF-1T20, 200, 230 OLYMPUS, Tokyo, Japan) were used. Cannulation of the desired duct was achieved in 124 of 164 patients (75.6 %): ERCs in 98 of 124 patients (79.0 %) and ERPs in 26 of 40 patients (65.0 %). Complications occurred in 4 patients (retroperitoneal perforation in 3, and bleeding in one). The reasons for failure of ERCP given by the author included: the afferent loop was too long to reach the papilla (25 patients), the papilla was identified but cannulation failed (10 patients), the papilla was not identified in spite of reaching the duodenal stump (3 patients), and the afferent loop could not be entered (2 patients). The author added that oblique-viewing endoscopes were superior to duodenoscopes in reaching the papilla and in bile duct cannulation in his recent experience [4].

Experienced biliary endoscopists should be able to successfully perform ERCP in most patients with Billroth II reconstruction. Unfortunately, the success rate in patients with Roux-en-y reconstruction still remains lower, and the complication rate of ERCP in patients who have undergone intestinal reconstruction (Billroth II and Roux-en-y) is not very low.

Endoscopic retrograde cholangiopancreatography and endoscopic nasobiliary drainage are useful procedures for cholangitis, jaundice, and bile leakage [1, 2, 9]. Since 1988, we have adopted 5Fr ENBD tubes (ENBD-5 Wilson-Cook Medical Inc. Winston-Salem, USA) for biliary drainage. This 5Fr ENBD tube can be inserted without sphincterotomy, and the drainage effect is adequate. This tube allows cholangiography to be performed at any time after placement. Before ENBD insertion, we performed endoscopic retrograde cholangiography routinely. We use this procedure as the treatment of first choice for obstructive jaundice secondary to choledocholithiasis [10].

In Japan, as well as in many other countries, Roux-en-y esophagojejunostomy, although not a physiologic route, apparently is the preferred reconstruction because it is relatively simple to perform and prevents reflux esophagitis. Since Schlatter performed the first successful total gastrectomy [11],

many types of gastric replacement with various enteric reservoirs have been applied in an effort to improve the symptoms or nutrition of the patients after total gastrectomy [5]. Since 1991, we have performed jejunal pouch double tract reconstruction after total gastrectomy and the postoperative course have been satisfactory as already been described in previous reports [6, 7]. Briefly, to construct a jejunal pouch, the distal portion of the divided afferent limb, 15 cm distal to the ligament of Treitz, is brought up posteriorly to the colon. At the end of the plicated proximal efferent loop, a 10-cm jejunal pouch is created with a linear autosuture stapler (GIA 90 U.S. Surgical Corp., USA). After inspecting of the anastomotic lines for hemostasis, double tract reconstruction is performed, Distal anastomosis, a jejunojejunostomy, is performed first, and then a second duodenojejunostomy is made with a circular stapling device (EEA 25, U.S. Surgical Corp., USA). Subsequent anastomosis to the esophagus is made by using a circular stapling device (PCEEA 25, U.S. Surgical Corp. USA). Reconstruction is completed by closing the proximal end of the efferent loop with a linear autosuture stapler (TA55 U.S. Surgical Corp. USA).

We encountered two cases of biliary tract disorders after total gastrectomy with jejunal pouch double tract reconstruction: choledocholithiasis in one and bile leakage after cholecystectomy due to acute emphysematous cholecystitis in the other. In each case, we performed ERCP with a conventional side-view endoscope (JF TYPE 1T30 OLYMPUS, Tokyo, Japan). The ENBD tube placement for the biliary tract complication the same as in ordinary patient without any special equipment. The method was the same as the maneuvers in patients who have not undergone intestinal reconstruction. In addition, when advancing the scope into the duodenum, the circular stapler used for duodenojejunostomy was a good landmark indicating the direction of the duodenum under fluoroscopy guidance.

CONCLUSION

We encountered biliary tract complications in two patients after total gastrectomy with JPD reconstruction. In both cases, endoscopic retrograde cholangiopancreatography and endoscopic nasobiliary drainage tube

placement were easily and safely performed by the same maneuvers as in ordinary patients. ERCP and ENBD tubes are useful for biliary tract disease in total gastrectomy patients with JPD reconstructions, as well as in ordinary patients.

REFERENCES

- 1) Mark Topazian, Richard Kozarek, Robert Stoler, Ronald Vender, Carolyn K. Wells, Alvan R. Feinstein: Clinical utility of endoscopic retrograde cholangiopancreatography. *Gastrointestinal Endoscopy* 46, 5, 393-399, 1997.
- 2) Yasuo Ohtani, Yutaka Tanaka, Masaru Tsukui, Kousuke Tobita, Takafumi Sekka, Yoshinori Sugio, Tomoo Tajima, Hiroyasu Makuuchi: Is it necessary to use the EST for common bile duct stones?. *Journal of clinical surgery* 53, 1, 43-46, 1998. (In Japanese)
- 3) R. E. Hintze, A. Adler, W. Veltzke, H. Abou-Rebeyh: Endoscopic access to the papilla of Vater for endoscopic retrograde cholangiopancreatography in patients with Billroth II or Roux-en-Y gastrojejunoanastomosis. *Endoscopy*, 29, 69-73, 1997.
- 4) Naoyuki Furuya, Kenji Mukawa, Shinya Maejima: Endoscopic retrograde cholangiopancreatography in patient with Billroth II gastrectomy. *Gastroenterological Endoscopy* 39, 12, 2446-2453, 1997.
- 5) Yasushi Nakane, Syunichiro Okumura, Kenji Akehira, Shigeo Okumura, Tsunehide Boku, Tokio Okusa, Kenji Tanaka, Koshiro Hioki: Jejunal Pouch Reconstruction After Total Gastrectomy for Cancer. A Randomized Controlled Trial. *Ann Surg* 222, 27-35, 1995.
- 6) Yasumasa Kodoh, Kenji Ishikawa, Takayuki Nishi, Yasuhiro Suzuki, Kousuke Tobita, Kenji Nakamura, Masao Miyaji, Kyouji Miyaji, Hiroyasu Makuuchi, Tajima Tomoo, Toshio Mitomo: Izentekigo no kuhchou pauchi daburutorakutohou ni yoru saiken-jutu. *Shujutu* 51, 1325-1330, 1997. (In Japanese)
- 7) Yasumasa Kondoh, Yasuo Kajiuura, Kenji Nakamura, Masao Miyaji, Kyoji Ogoshi, Tomoo Tajima, Hiroyasu Makuuchi: Jejunal pouch double tract versus Reux-en-Y reconstruction after total gastrectomy for cancer. *Jpn J Gastroenterol Surg* 32, 4, 978-982, 1999. (In Japanese)
- 8) Shunsuke Hara, Kyoji Ogoshi, Toshio Mitomi: Ultrasonic findings of the cholecyst and biliary tract after gastrectomy. *Journal of Japan surgical Society*, 94 352-358, 1993. (In Japanese)
- 9) Kenichiro Goto, Yutaka Tanaka, Yasuo Ohtani, Toshio Mitomi: Treatment and strategy of Gallstone under special conditions Gallstones in the elderly. *Nipponrinsho* 51, 7181-186, 1993. (In Japanese)
- 10) Yasuo Ohtani, Yutaka Tanaka, Kenichiro Goto, Masara Tsukui, Hiroyasu Makuuchi, Tomoo Tajima, Toshio Mitomi: Extracorporeal shock wave lithotripsy for choledocholithiasis. *Journal of Japan surgical Society* 9, 1123-1127, 1992. (In Japanese)
- 11) Schlatter CA: A unique case of complete removal of the stomach with successful esophagoenterostomy recovery. *Med Res* 52, 909-912, 1987.