

Fatal adenovirus infection indistinguishable from thrombotic microangiopathy after allogeneic CD34⁺ peripheral progenitor cell transplantation

Hiromasa YABE, Kinya HATTORI, Hiroyasu INOUE, Masae MATSUMOTO, Satoshi HAMANOUE, Aiko HIROI, Takashi KOIKE, Shunichi KATO*, Kazuo SHIMAMURA** and Miharuru YABE

Specialized Clinical Science, Pediatrics,

**Department of Cell Transplantation and Regenerative Medicine,*

***Department of Pathology, Tokai University School of Medicine*

(Received Jun 8, 2004; Accepted January 5, 2005)

A 10-year-old boy with acute lymphoblastic leukemia in second relapse received CD34⁺ purified allogeneic peripheral blood stem cell transplantation (PBSCT) from his HLA-haploidentical father. The patient developed grade II acute GVHD and received high-dose methyl-prednisolone starting on day +13 posttransplant. Renal dysfunction followed by massive gastrointestinal bleeding was observed from day +14. The laboratory findings including elevated serum LDH, increased RBC fragmentation, higher level of thrombomodulin and undetectable haptoglobin corresponded with the diagnosis of thrombotic microangiopathy (TMA). In spite of various treatments, the patient died of multiple organ failure on day +93. Post-mortem examination revealed systemic adenovirus infection without histological findings of TMA. Severe adenovirus infection may be confused with TMA, and should be distinguished by rapid virological assay.

Key words : CD34⁺ cell transplantation, adenovirus infection, thrombotic microangiopathy

INTRODUCTION

Recent advances have decreased the incidence of severe acute GVHD after allogeneic BMT from HLA-matched siblings and even from HLA-mismatched related donors. Moreover, CD34-positive cell selection has enabled stem cell grafting from HLA-haploidentical donors [1, 2]. However, eliminating T-cells from the bone marrow (BM) or peripheral blood stem cells (PBSC) has resulted in an increased incidence of severe infection. Most infections after CD34-selected transplantation are potentially life-threatening, including cytomegalovirus (CMV) interstitial pneumonitis, Epstein-Barr virus (EBV)-related B-cell lymphoproliferative disorder (BLPD). Infection with adenovirus may cause interstitial pneumonitis, hepatitis, and hemorrhagic cystitis after conventional

BMT [3-5], but hemorrhagic enterocolitis has not been noted until now. Moreover, it has not been emphasized that the laboratory findings of severe adenovirus infection is similar to that of TMA.

We report a case of fatal hemorrhagic enterocolitis caused by adenovirus indistinguishable from severe thrombotic microangiopathy (TMA) after CD34-selected PBSCT.

CASE REPORT

A 10-year-old boy with pre-B ALL in second relapse received a stem cell transplant from his HLA-haploidentical father on November 4, 1998 because an HLA-suitable donor was not found through the Japan marrow donor program (JMDP) or the national marrow donor program (NMDP). Unrelated cord blood bank was not available on that time. He had good performance

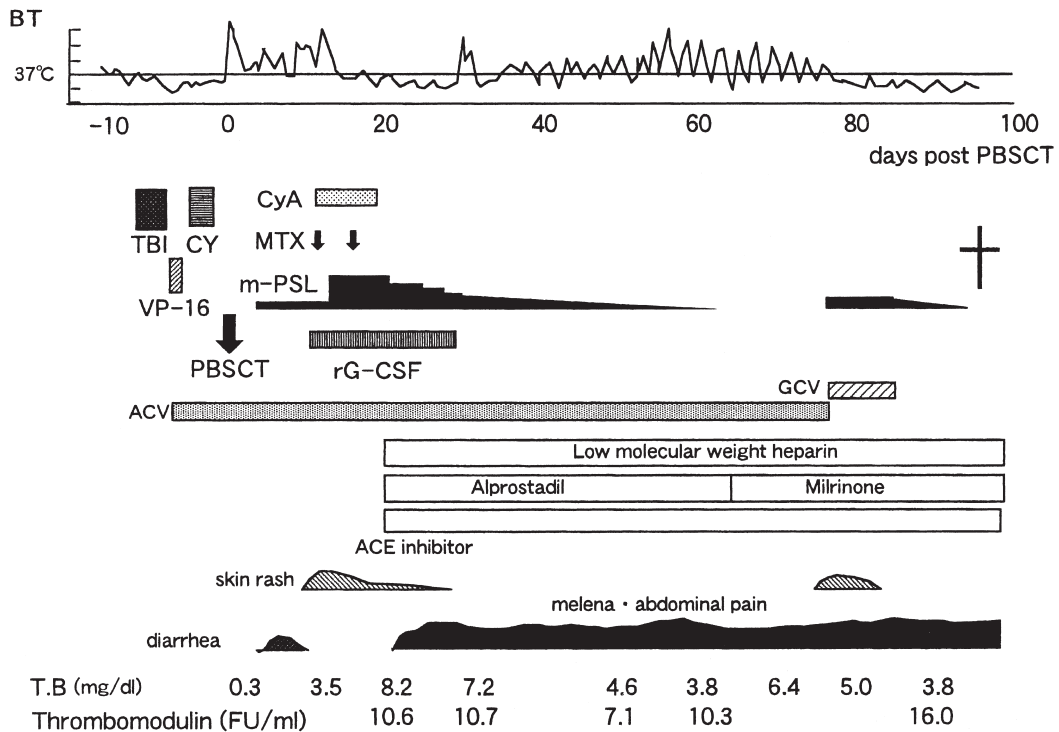


Fig. 1 Clinical course of the patient.

BT indicates body temperature; TBI, total body irradiation; VP-16, etoposide; CY, cyclophosphamide; PBSCT, peripheral blood stem cell transplantation; CyA, cyclosporine A; MTX, methotrexate; m-PSL, methylprednisolone; rG-CSF, recombinant granulocyte-colony stimulating factor; ACV, aciclovir; GCV, ganciclovir; ACE, angiotensin-converting enzyme; TB, total bilirubin.

status, normal physical examination, and no active infection. CD34⁺ purification from granulocyte-colony stimulating factor (G-CSF)-mobilized PBSC was used for prophylaxis of GVHD. Written informed consent was obtained from his parents, and this procedure was approved by the ethics committee of Tokai University.

The conditioning regimen consisted of TBI, etoposide (VP-16), and cyclophosphamide (CY). TBI was given in a total dose of 12 Gy in 5 fractions on days -8 to -6, etoposide was given in a dose of 60 mg/kg on day -5, and CY was administered in a dose of 60 mg/kg/day on days -3 to -2. The date of first stem cell infusion was designated as day 0. For stem cell mobilization, the donor received 10 µg/kg G-CSF (filgrastim) on days -5 to 0, and leukapheresis was performed on days 0 and +1. The apheresis products were processed for CD34⁺ purification using the Isolex 50 cell

separation system (Baxter-Immunotherapy, Santa Ana, CA). PBSC were infused into the patient through a central venous catheter on day 0 and +1. The total CD34 dose was 18.9×10^6 /kg, with a total of 11.3×10^4 /kg of CD3⁺ cells. G-CSF was not administered after stem cell grafting, and prophylaxis for GVHD was not given. The clinical course is shown in Fig. 1.

Hematologic recovery was prompt, with absolute neutrophils $>0.5 \times 10^9$ /l on day +11, and white blood cells $>1 \times 10^9$ /l on day +12. However, recovery of both red blood cells and platelets was delayed, and the patient was dependent on transfusion. Engraftment was confirmed by HLA typing on day +14. *Staphylococcus epidermidis* sepsis was diagnosed on day +1, and antibiotics were administered. Although sepsis abated, fever persisted, and diarrhea developed on day +4. Because preconditioning-induced diarrhea was suspected, 1 mg/kg/day of

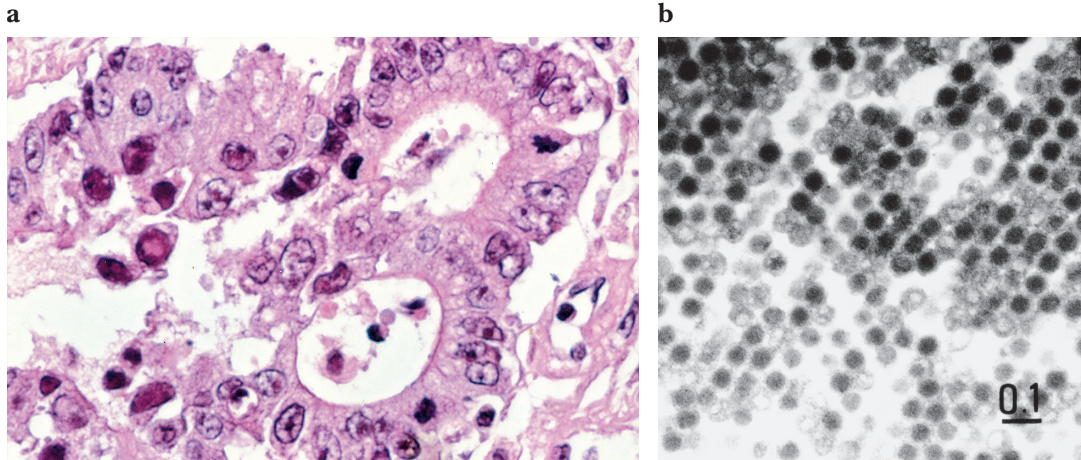


Fig. 2 a: There is severe degeneration and necrosis of intestinal epithelial cells associated with intranuclear inclusions and 'smudge cells' by light microscopy. Hematoxylin and eosin, orig. mag. $\times 250$.

b: There are many viral particles, which diameters were about 80 nm and were arranged, in orderly rows in intestinal epithelial cells. These electron-microscopic findings were corresponding to adenovirus infection.

prednisolone (PSL) was administered, and the fever resolved. The fever recurred on day +7, and skin rash developed on day +11. Acute GVHD was suspected, and the PSL dose was increased to 2 mg/kg/day. The skin rash became systemic erythema, and the total bilirubin began to increase on day +13, therapy was changed to high-dose methyl-prednisolone (methyl-PSL) at 1 g/m²/day, methotrexate at 15 mg/m², and cyclosporine A (CyA) at 3 mg/kg. The fever and skin rash resolved immediately, and diarrhea disappeared within 3 days. However, total bilirubin increased to 5.0 mg/dl on day +17, and massive gastrointestinal bleeding, over 2 l/day, developed on day +20. Leukopenia, renal dysfunction, elevated lactate dehydrogenase, fragmented RBCs and increased thrombomodulin were observed. Serum haptoglobin was under the detectable level. Because thrombotic microangiopathy (TMA) was suspected, CyA was stopped, and methyl PSL was tapered rapidly. Massive melena persisted, and intensive treatment including low molecular weight heparin, angiotensin-converting enzyme inhibitor, fresh-frozen plasma, and prostaglandin E was instituted. In spite of these intensive treatments, the patient died of multiple organ failure on day +93. Both elevated lactate dehydrogenase and increased thrombomodulin had

persisted until the time of death.

Weekly examination for CMV antigenemia showed only a single positive (2 per 15×10^4 cells) study on day +33, and EBV genome-PCR was persistently negative.

Results of postmortem examination

By light microscopy, there was severe degeneration and necrosis of intestinal epithelial cells associated with intranuclear inclusions and 'smudge cells' characteristic of adenovirus infection (Fig. 2a). Nuclear inclusion bodies in the epithelial cells of the bronchi were also observed. There were many viral particles, which diameters were about 80 nm and were arranged, in orderly rows (Fig. 2b). These electron-microscopic findings were corresponding to adenovirus infection.

Cutaneous and intestinal GVHD were observed; however, both changes were mild and did not contribute to the cause of death. There were no microthrombi in the intestinal vessels, and in other organs, and TMA was not found.

DISCUSSION

Adenovirus infection in patients receiving stem cell grafting can be a significant cause of morbidity and mortality. Adenovirus has been isolated from many sites in 5 to 20% of patients undergoing BMT and has been

shown to cause invasive disease in 20% of these patients. As a clinical manifestation, severe pneumonitis, hepatitis with or without hepatic necrosis, pancreatitis, hemorrhagic cystitis, nephritis, and disseminated disease have been reported. Some patients develop gastroenteritis, but the frequency of massive gastrointestinal bleeding is low. Our case presented with massive intestinal hemorrhage and TMA-like findings, including an elevated LDH schistocytes.

TMA usually occurs 1 to 6 months post-transplantation, and consists of thrombocytopenia and microangiopathic hemolytic anemia [6]. It is well known that the laboratory findings including elevated LDH, fragmented RBCs, and undetectable haptoglobin are necessary to diagnose TMA. Kanamori *et al.* [7] reported higher level of thrombomodulin was observed in patients with TMA. Zeigler *et al.* [8] developed a grading system for the severity of TMA based on the LDH level and the percentage of fragmented RBCs which correlated with poor outcome. We found that the laboratory findings of severe adenovirus infection may resemble that of TMA. It is shown that adenovirus infect and replicate in human venous endothelium [9]. This endothelial injury is important in the pathogenesis of thrombosis, disseminated intravascular coagulation, and vasculitis. Thus, severe adenovirus infection is considered to cause TMA-like laboratory findings.

TMA is associated with GVHD prophylaxis consisting of CyA and glucocorticoids with or without methotrexate [10, 11]. Our case developed renal dysfunction and massive melena soon after the starting high-dose methyl-PSL and CyA, mimicking the onset of TMA. High-dose methyl-PSL for the treatment of acute GVHD may also induce viral reactivation.

One of the major causes of fatal adenovirus infection is delayed recovery of immunocompetent cells after CD34⁺ cell transplantation. Severe viral infection often complicates T-cell-depleted BMT as a result of delayed immune reconstitution. Since the residual T-cell number after CD34⁺ selection is less than one-tenth of those remaining after conventional T-cell depletion [1], T-cell recovery after CD34⁺ selected transplantation is much slower. To improve immune recovery after CD34⁺ selected transplantation, rG-CSF mobilized PB was used instead of BM

because faster recovery of T-cells is obtained after allotransplantation of PBSC compared to BM [12] with or without CD34⁺ selection. However, even after autotransplantation of PB CD34⁺ cells, the incidence of CMV infection is much higher than with unseparated PBSCT. Childs *et al.* [13] reported that 9 of 56 patients who received T-cell depleted BMT and CyA developed a viral infection (adenovirus in 4, and polyomavirus in 4). Although hemorrhagic cystitis is not associated with the dose of CD34⁺ progenitors or CD3⁺ cells, life-threatening adenovirus-induced hemorrhagic cystitis may be caused by immunodeficiency after T-cell depleted BMT. A higher incidence of viral reactivation was reported by Matsuda *et al.* [14] for CMV and human herpesvirus-6 among 5 CD34⁺ purified PBSC recipients. Chakrabarti *et al.* [15] reported that adenovirus infection occurred in 15 of 62 recipients of T-cell depleted grafts, compared with none of 14 patients receiving unmanipulated grafts. Early detection of viral reactivation using polymerase-chain reaction based assay or enzyme-linked immunosorbent assay should be performed, and treatment including antiviral drugs, and donor lymphocyte infusion should be instituted when adenovirus infection is suspected after CD34⁺ selected PBSCT or T-cell depleted BMT.

ACKNOWLEDGMENT

The authors thank the medical, nursing, laboratory staff of the participating institutions for their important contributions to this study, including the careful and dedicated care of the patients. This work was supported in part by research fund # H15-RM-012 for Health and Labor Science Research Grants, Research on Human Genome, Tissue Engineering Food Biotechnology, Ministry of Health, Labor and Welfare.

REFERENCES

- 1) Yabe H, Yabe M, Hattori K, *et al.* Successful engraftment of allogeneic CD34-enriched marrow cell transplantation from HLA-mismatched parental donors. *Bone Marrow Transplant* 1996; 17: 985-991.
- 2) Kato S, Yabe H, Yasui M, *et al.* Allogeneic hematopoietic transplantation of CD34⁺ selected cells from an HLA haplo-identical related donor; a long-term follow-up of 135 patients and a comparison of stem cell source between the bone marrow and the peripheral blood. *Bone Marrow Transplant*. 2000; 26: 1281-1290.

- 3) Shields AF, Hackman RC, Fife KH, *et al.* Adenovirus infections in patients undergoing bone-marrow transplantation. *N Engl J Med* 1985; 312: 529-533.
- 4) Hale GA, Heslop HE, Krance RA, *et al.* Adenovirus infection after pediatric bone marrow transplantation. *Bone Marrow Transplant* 1999; 23: 277-282.
- 5) Ikegami K, Takimoto, T, Takahashi R, *et al.* Lethal adenovirus infection in a patient who had undergone nonmyeloablative stem cell transplantation. *Int J Hematol* 2001; 74: 95-100.
- 6) Holler E, Kolb HJ, Hiller E, *et al.* Microangiopathy in patients on cyclosporine prophylaxis who developed acute graft-versus-host disease after HLA-identical bone marrow transplantation. *Blood* 1989; 73: 2018-2024.
- 7) Kanamori H, Maruta A, Sasaki S, *et al.* Diagnostic value of hemostatic parameters in bone marrow transplant-associated thrombotic microangiopathy. *Bone Marrow Transplant* 1998; 21: 705-709.
- 8) Zeigler ZA, Shaddock RK, Nemunaitis DF, *et al.* Bone marrow transplant-associated thrombotic microangiopathy: a case series. *Bone Marrow Transplant* 1995; 15: 247-253.
- 9) Friedman HM, Macarak EJ, MacGregor RR *et al.* Virus infection of endothelial cells. *J Infect Dis* 1981; 143: 266-273.
- 10) Kalhs P, Brugger S, Schwarzwinger I, *et al.* Microangiopathy following allogeneic bone marrow transplantation. *Transplantation* 1995; 60: 949-957.
- 11) Paquette RL, Tran L and Landaw EM. Thrombotic microangiopathy following allogeneic bone marrow transplantation is associated with intensive graft-versus-host disease prophylaxis. *Bone Marrow Transplant* 1998; 22: 351-357.
- 12) Ottinger HD, Beelen DW, Scheulen B, *et al.* Improved immune reconstitution after allotransplantation of peripheral blood stem cells instead of bone marrow. *Blood* 1996; 88: 2775-2779.
- 13) Childs R, Sanchez C, Engler H, *et al.* High incidence of adeno- and polyomavirus-induced hemorrhagic cystitis in bone marrow allotransplantation for hematological malignancy following T cell depletion and cyclosporine. *Bone Marrow Transplant* 1998; 22: 889-893.
- 14) Matsuda Y, Hara J, Osugi Y, *et al.* Allogeneic peripheral stem cell transplantation using positively selected CD34⁺ cells from HLA-mismatched donors. *Bone Marrow Transplant* 1998; 21: 355-360.
- 15) Chakrabarti S, Mautner V, Osman H, *et al.* Adenovirus infections following allogeneic stem cell transplantation: incidence and outcome in relation to graft manipulation, immunosuppression, and immune recovery. *Blood* 2002; 100: 1619-1627.