

Effects of Low-frequency Repetitive Transcranial Magnetic Stimulation on Focal Hand Dystonia: A Case Report

Toshiaki FURUKAWA^{*1}, Hidenori KANKE^{*1} and Yoshihisa MASAKADO^{*2}

^{*1}*Department of Rehabilitation Medicine, Tokai University Hachioji Hospital*

^{*2}*Department of Rehabilitation Medicine, Tokai University School of Medicine*

(Received December 8, 2020; Accepted January 18, 2021)

A 40-year-old female patient with no medical history or family history of dystonia showed no abnormalities on cranial MRI. However, flexions and extensions were poor during the right arm and elbow movements, and tremors were observed during the finger separation movement. The tremors reduced when the left hand was placed on the right shoulder. The patient was, therefore, diagnosed with right hand dystonia and treated with repetitive transcranial magnetic stimulation (rTMS) therapy. The motor cortex regulating the right arm was stimulated with a 1 Hz rTMS, performed 350–500 times at an intensity 1.2 times of that of the threshold value. When involuntary movements improved after 350 times, we measured the simple test for evaluating hand function (STEF), and finger-bending and writing movements before and after stimulation by monitoring the changes in cerebral blood flow using near-infrared spectroscopy (NIRS). We also assessed the motor evoked potential (MEP), cortical silent period (CSP), and short-interval intracortical inhibition (SICI) before TMS and after 150 times and 350 times. The arm movement was recorded as a video.

After 150 stimulations of rTMS, the right arm and finger separation movements improved; after 350 stimulations, movements became very quick and comparable with those of the left side. There were clear improvements in STEF and writing. Although there was no significant change in MEP, we observed a prolonged CSP latency and a significant decrease in the SICI ratio. NIRS evaluations showed that changes in the relative concentrations of hemoglobin (Hb) in the left motor cortex regulating the right finger movement after rTMS were minimal when compared to that before rTMS; however, a significant decline was seen in the left premotor and prefrontal cortexes. A decline in the writing movement was seen in the left motor, premotor, and prefrontal cortexes. However, symptoms improved and remained stable for a long time with low-frequency rTMS.

We experienced a case of upper limb dystonia where low-frequency, above-threshold rTMS on the motor cortex showed significant effects. Changes in plasticity were seen in long-term rTMS. NIRS was validated as a useful index of indirect brain function for observing the effects of rTMS.

Key words: Hand dystonia, Low-frequency Repetitive Transcranial Magnetic Stimulation, Near-infrared spectroscopy, Plasticity

INTRODUCTION

There is still no effective drug or complementary therapy that can cure dystonia. Dystonia is caused by the dysfunction of the motor loop comprising the cerebral cortex (sensory/motor cortex and premotor cortex, and supplementary motor cortex)–basal ganglia–thalamus–cerebellar cortex circuit [1, 2], peripheral depressive disorder of the cerebral cortex [3], sensorimotor-related abnormalities [4], neuroplasticity abnormalities, neural network abnormalities of the cerebellum, brain stem, or spinal cord, and peripheral neuropathy [5–7].

Therefore, the complexity, unresolved pathophysiology mechanisms, and ambiguous symptom expression patterns make the disease difficult to treat.

Neurophysiological assessments of dystonia have reported a decline in cortical silent period (CSP) latency and short-interval intracortical inhibition (SICI) with transcranial magnetic stimulation (TMS), suggesting increased excitability of the corticocerebral motor cor-

tex [8–10].

Repetitive TMS (rTMS) is effective in persistently altering the excitability of the cerebral cortex; low-frequency rTMS reduces the excitability. This has been used to improve symptoms in Parkinson's disease [11, 12] and depression [13].

Numerous studies have reported the use of low-frequency rTMS for dystonia in sites, such as the motor, premotor, supplementary motor, and sensory cortexes [8, 14–17].

Here, we report a case of dystonia where a low-frequency, above-threshold rTMS showed immediate and long-term effectiveness. The immediate effects were evaluated with near-infrared spectroscopy (NIRS).

CASE PRESENTATION

The patient was a 40-year-old woman, a housewife, with no family history of illness. About ten years ago, she noticed her right hand trembling and interfering with her daily life activities, including, writing and

cutting vegetables. A request was made to the rehabilitation department due to difficulty in moving the upper right arm and fingers. The patient had no medical history, including that of an injury or brain disorder, and no abnormalities were found in cranial MRI scans. However, the right wrist and elbow joints moved abnormally during flexion and extension, and effort was required to separate the fingers. Tremors were felt in the right arm and fingers during elbow extension. Placing the left hand on the right shoulder worked as a sensory trick and alleviated the tremors. Surface electromyograms showed co-contraction in the flexor (flexor carpi radialis and flexor carpi ulnaris) and extensor (extensor carpi radialis and extensor carpi ulnaris) muscles of the right forearm during flexion and extension of the right wrist joint.

The patient was, therefore, diagnosed with focal hand dystonia. The patient had no previous experience with botulinum toxin treatment or any other treatment.

Almost no drugs have evidence to support their use in the treatment of dystonia, and although botulinum toxin therapy in muscle exhibiting abnormal contraction is a peripheral therapeutic option, the rate of remission with this treatment is not high. Moreover, botulinum toxin therapy can increase tone in untreated muscles and induce abnormal posture. For these reasons, we chose a treatment targeting the central nervous system, namely low-frequency rTMS.

Approval was obtained from the ethics committee of Tokai University School of Medicine and consent was obtained from the patient.

rTMS was conducted two to three times on each of the stimulation sites, left prefrontal, supplementary motor, premotor, and motor cortices, at 1 Hz and 90%, 120% of the resting motor threshold. An rTMS above the threshold was chosen based on the patient's experience with its effectiveness on the left motor cortex.

SMN-1200 stimulator with eight coils (Nihon Kohden Corporation, Japan) was used for TMS and rTMS. Neuropack Micro (MEB-9104, Nihon Kohden Corporation, Japan) was used to derive the motor evoked potentials (MEP), and surface electrodes were placed in the left first dorsal interosseous (FDI) muscle for recording.

rTMS was applied to the motor cortex regulating the right arm at 1.2 times the resting threshold, with up to 500 stimulations at 1 Hz. The number of stimulations continued until the upper limit of 500 times was reached or sufficient improvements in involuntary movements were seen (i.e., movements were equivalent to those of the left hand).

Low-frequency rTMS at or below 1 Hz is considered safe up to 1,500 stimulations/week. According to international safety standard guidelines, it is considered safe at up to 1,800 stimulations when performed below the resting motor threshold.

The Japanese Society of Clinical Neurophysiology committee on magnetic stimulation recommends 1,500 stimulations/week as the upper limit when applied below the resting motor threshold. Meanwhile, treatment with 500 stimulations/week of above-threshold low-frequency rTMS has been associated with electroencephalographic abnormalities in patients with involuntary

movement.

Considering our patient would receive stimulation above the resting motor threshold, we set 500 stimulations as the upper limit and performed stimulation sessions once or twice per month while observing patient progress. A treatment duration of at least 1 year and 6 months was chosen because a minimum of 1 year of treatment was considered necessary to induce neural plasticity.

rTMS was performed 25 times over a period of 1 year and 10 months.

The finger bending and writing activities (i.e., writing name in Kanji) of the patient were measured before and after stimulation (on the 10 stimulation sessions) to evaluate the period required for stable improvements with treatment. The changes in cerebral blood flow (relative changes in oxygenated hemoglobin [oxy-Hb] and deoxygenated hemoglobin [deoxy-Hb] levels) were measured using the NIRS machine (FOIRE-300, Shimadzu Corporation, Japan) (Fig. 1). NIRS is a technique used for detecting hemoglobin level changes in the skull using near-infrared light, which has high biological permeability through the skin, skull, and cerebral tissues. Positron emission tomography (PET), single photon emission computed tomography, and functional magnetic resonance imaging are other methods used for capturing changes in cerebral blood flow associated with local nerve cell activity; however, NIRS is advantageous because it has fewer constraints on the movement of the subject. Near-infrared light passing between two fibers are used to measure changes in oxy-Hb and deoxy-Hb levels in the skull over time. NIRS evaluations conducted in our study measured changes in oxy-Hb and deoxy-Hb levels at 54 sites, including the bilateral motor, premotor, supplementary motor, and prefrontal cortices.

Neurophysiological evaluation was performed by assessing the MEP, CSP, and SICI before rTMS, after 150 times, and 350 times. MEP is a waveform recorded when the motor cortex is stimulated by TMS and is a basic index of motor cortex excitability with amplitude.

CSP is the time period where the muscle activity is suppressed for hundreds of ms after MEP when TMS singularly stimulates the contralateral motor cortex and contracts voluntary muscles. It is presumed that the late component of CSP, 50–100 ms after TMS, is involved in the inhibitory mechanism of the motor cortex.

SICI is an intracortical inhibitory effect obtained by two consecutive magnetic stimulations of the motor cortex measured using the method proposed by Kujirai *et al.* [18]. As per the method, the conditioned stimulus was set to the resting motor threshold (RMT) or lesser, the test stimulus was set to an intensity that induces contralateral MEPs in the hand muscles, and the two stimuli were connected to give two consecutive TMS values from one stimulation coil to the motor cortex. In our study, the conditioned stimulus was set to 0.8 MT for FDI, and the test stimulus was set to 1.2 MT with an interval of 3 ms. We calculated the SICI ratio by dividing the MEP value obtained with the test stimulus preceding the conditioned stimulus by the MEP value obtained with the test stimulus alone, at a stimulus interval of 3 ms – SICI ratio = MEP amplitude (mV) with the test stimulus preceded by the condi-

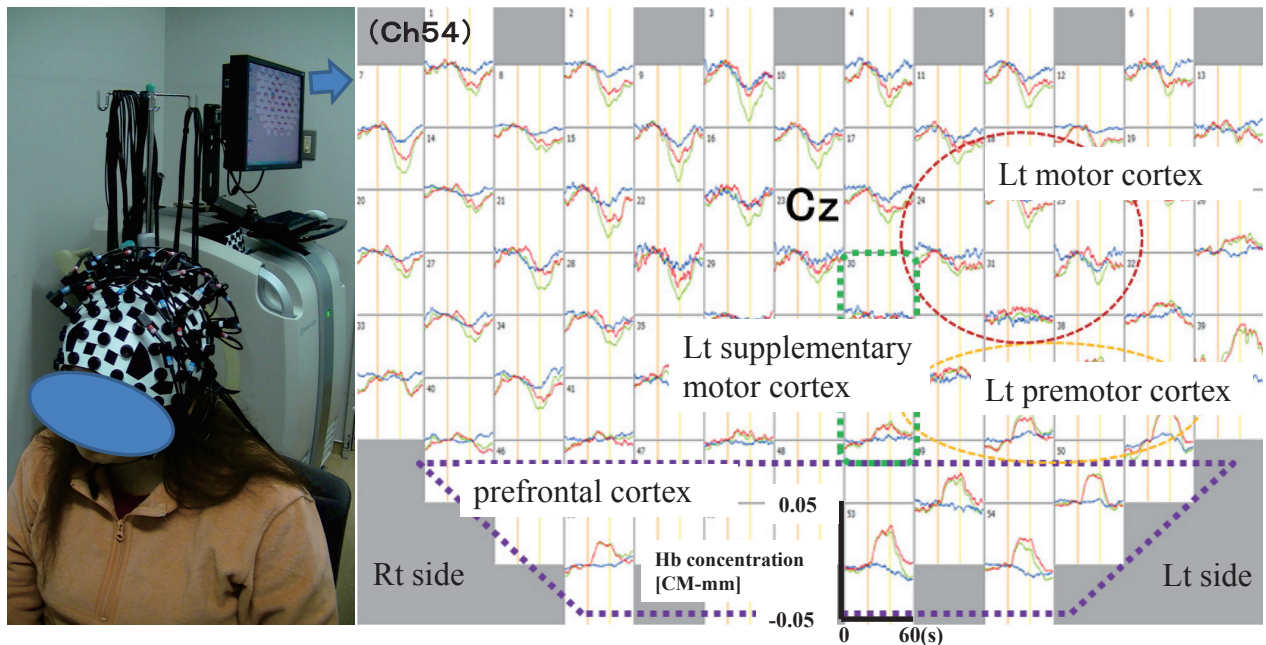


Fig. 1 Settings and channels of the NIRS transmitting and receiving fibers are shown. Changes in oxy-Hb and deoxy-Hb levels in 54 locations, including the bilateral motor cortex (red dashed line), premotor cortex (yellow dashed line), supplementary motor cortex (green dashed line), and prefrontal cortex (purple dashed line) were measured over time.

tioned stimulus/MEP amplitude (mV) with the test stimulus alone.

STEF analysis was performed to evaluate the functional movements of the right arm. The upper arm movements were recorded on video. STEF is an objective and simple evaluation method developed by Kaneko *et al.* [19] to evaluate the functional performance of the upper arm. It is composed of 10 subtests and uses a standardized test kit to assess tasks involving reaching, grasping, pinching, and manipulating objects of various shapes. The time required for each subtest is scored according to a score profile column on a 10-point score, and a total score is calculated for the left and right sides. The total score varies from 0 to 100 points. The advantage of this test is the objective quantification and evaluation of upper arm function, especially the speed of movement. STEF has been performed six times during the treatment.

No side effects were observed before and after stimulation and during the treatment.

The number of rTMS stimulations required in 25 stimulation sessions over the course of one year and nine months, until an improvement in involuntary movements were observed and divided as follows: sessions 1-4, slight improvements in tremors and separation of fingers on the right hand observed at 500 stimulations; sessions 5-14, the above improvements were observed at 300-375 (average = 342) stimulations; sessions 15-20, the above improvements were observed at 150-300 (average = 233) stimulations; sessions 21-25, significant improvements were observed at 150-250 (average = 190) stimulations. Sufficient improvements at lower numbers of stimulations were seen gradually over the course of rTMS. However, changes in the resting threshold were not evident (Fig. 2).

The total STEF score improved over the course of treatment. The total STEF score for the tests conducted between at 4 months (tests 3-5), was 44-46 points

before rTMS, which significantly improved during the course of treatment, to 98-99 after rTMS. The total STEF scores before rTMS for the test conducted at 1 year and 8 months (test 6), and the corresponding score after rTMS (Fig. 3) were higher than that of TMS results from the test conducted at 4 months (test 5).

The right limb and finger separation movements improved at around 150 stimulations. After 350 stimulations, the patient's movements were very quick and the functions were similar between the left and the right side; writing had also significantly improved (Fig. 4). TMS evaluation showed a prolonged CSP latency and a significant decrease in the SICI ratio (Fig. 5, 6). NIRS evaluations showed insignificant changes in the Hb levels in the left motor and supplementary motor cortices determined based on finger-bending movements measured before and after rTMS; however, a decline was observed in the left premotor and prefrontal cortices. Writing activities also resulted in reductions in Hb levels in the left motor, supplementary motor, premotor, and prefrontal cortices.

DISCUSSION

We performed a low-frequency, above-threshold rTMS on the left motor cortex for right-hand dystonia and observed its immediate and long-term effects. No side effects were observed before and after rTMS and during the treatment.

The results of rTMS conducted on the 10 stimulation sessions, showed improvements in the right arm function and finger separation at around 150 stimulations. After 350 stimulations, movements were so quick that differences between the left and right side were negligible, and significant improvements were seen in the writing ability.

NIRS results showed that changes in oxy-Hb levels in the left motor cortex due to right finger-bending movements were relatively small after rTMS when

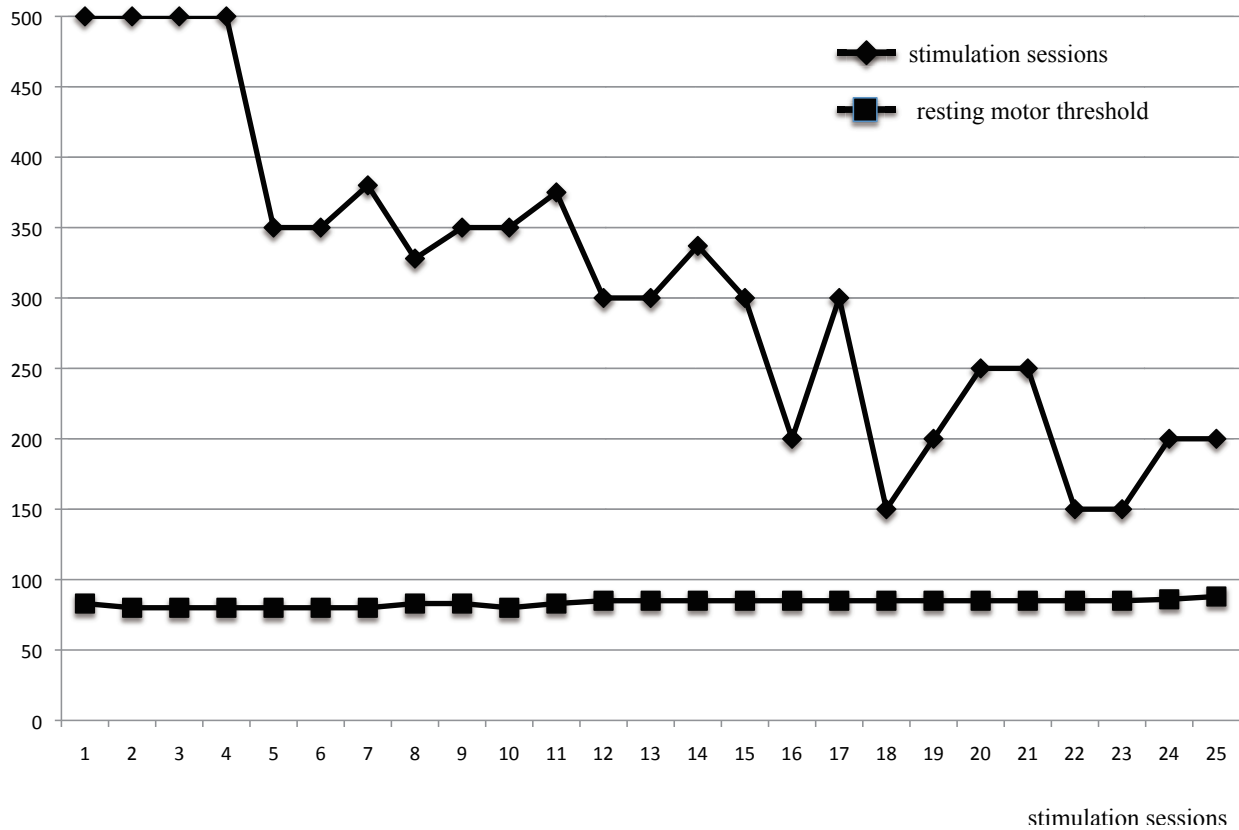


Fig. 2 The number of rTMS stimulations required until involuntary movements improved and the resting threshold values in the 25 stimulation sessions during the course of one year and nine months are shown. Adequate improvements were seen with fewer stimulations over the course of rTMS. There were no clear changes in the resting threshold.

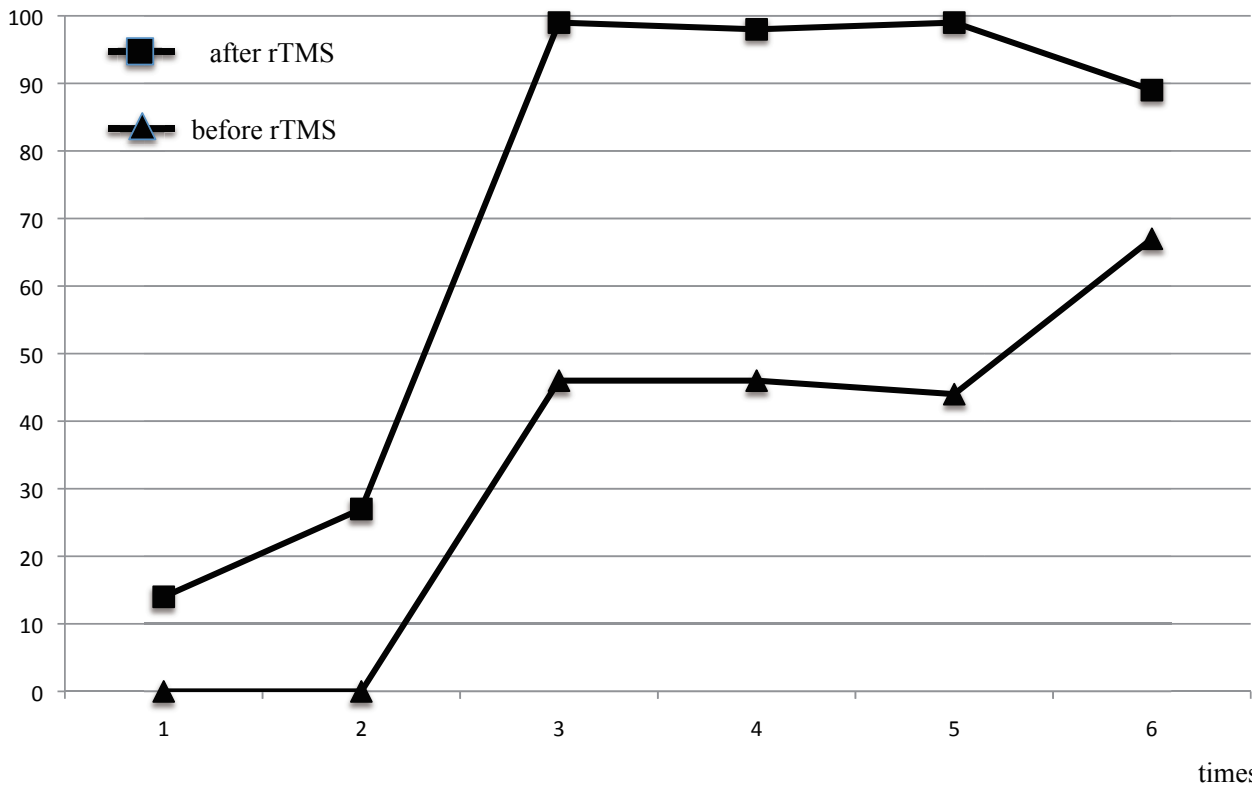


Fig. 3 The times and scores of the total STEF test conducted before and after rTMS are shown. These were conducted six times during the course of treatment. The total STEF score improved during the course of treatment. The total STEF score before rTMS conducted at 4 months (tests 3-5) was 44-46 points which significantly improved to 98-99 points during the course of rTMS treatment. The total STEF scores before and after rTMS at 1 year and 8 months (test 6) further improved.

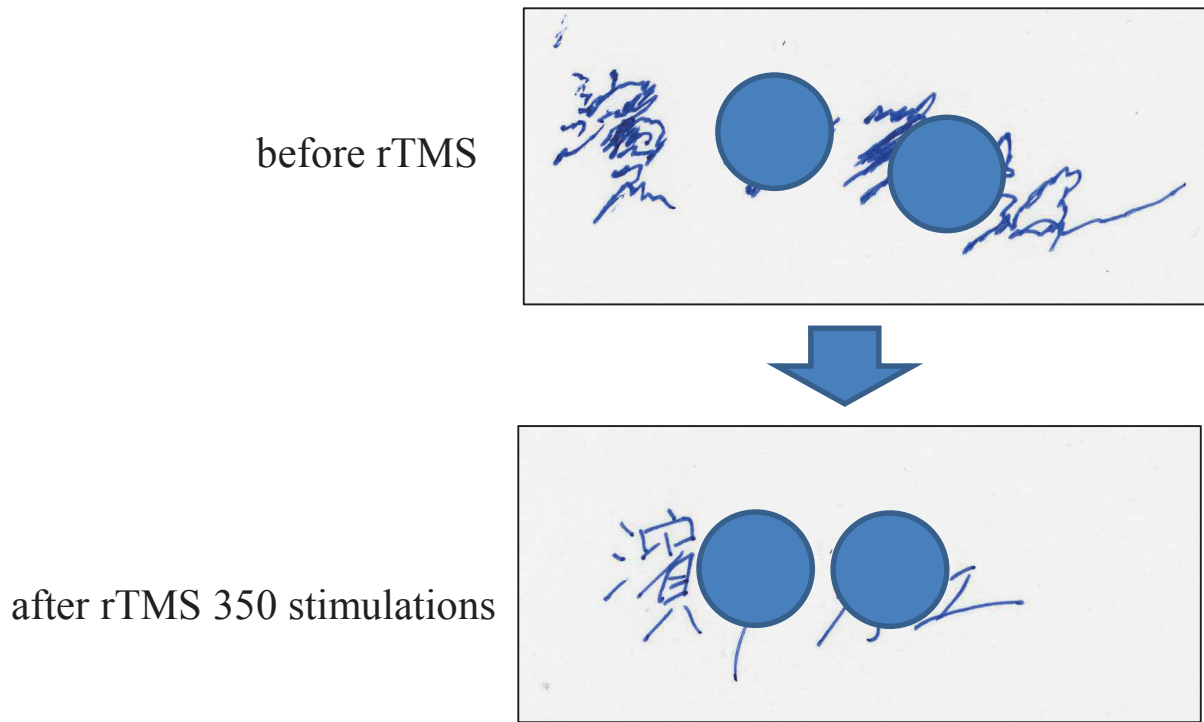


Fig. 4 Changes in writing (name in Kanji) before rTMS and after 350 stimulations are shown. Clear improvements in writing are seen.

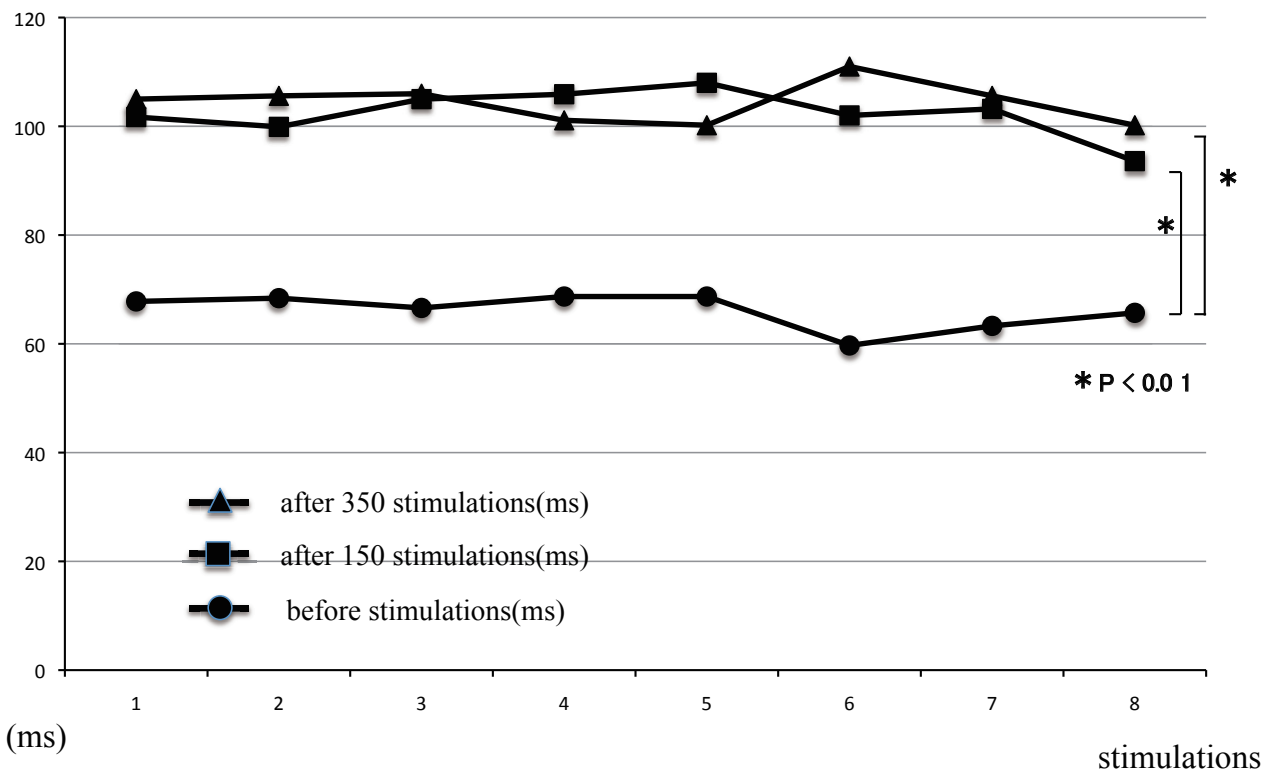


Fig. 5 Changes in CSP latency are shown before rTMS, and after 150 and 350 stimulations. Eight sessions were conducted, and significant prolongation was seen after 150 and 350 stimulations compared to that before rTMS.

compared to that before rTMS, but the levels decrease in the left premotor and prefrontal cortices. A relative decrease in the oxy-Hb levels was observed during writing activities (i.e., writing name) in the left motor, premotor cortex, and prefrontal cortices.

TMS evaluations showed a prolonged CSP latency and a significantly decreased SICI ratio.

Immediate effects were measured as changes in the

cerebral blood flow during finger bending movements and writing activities of the right hand before and after rTMS, using NIRS. The effects were also measured as changes in CSP and SICI scores, which evaluated the intracortical inhibitory neurons.

NIRS measures change in hemoglobin levels in the capillaries and veins. Animal trials have shown that changes in cerebral blood flow were highly correlated

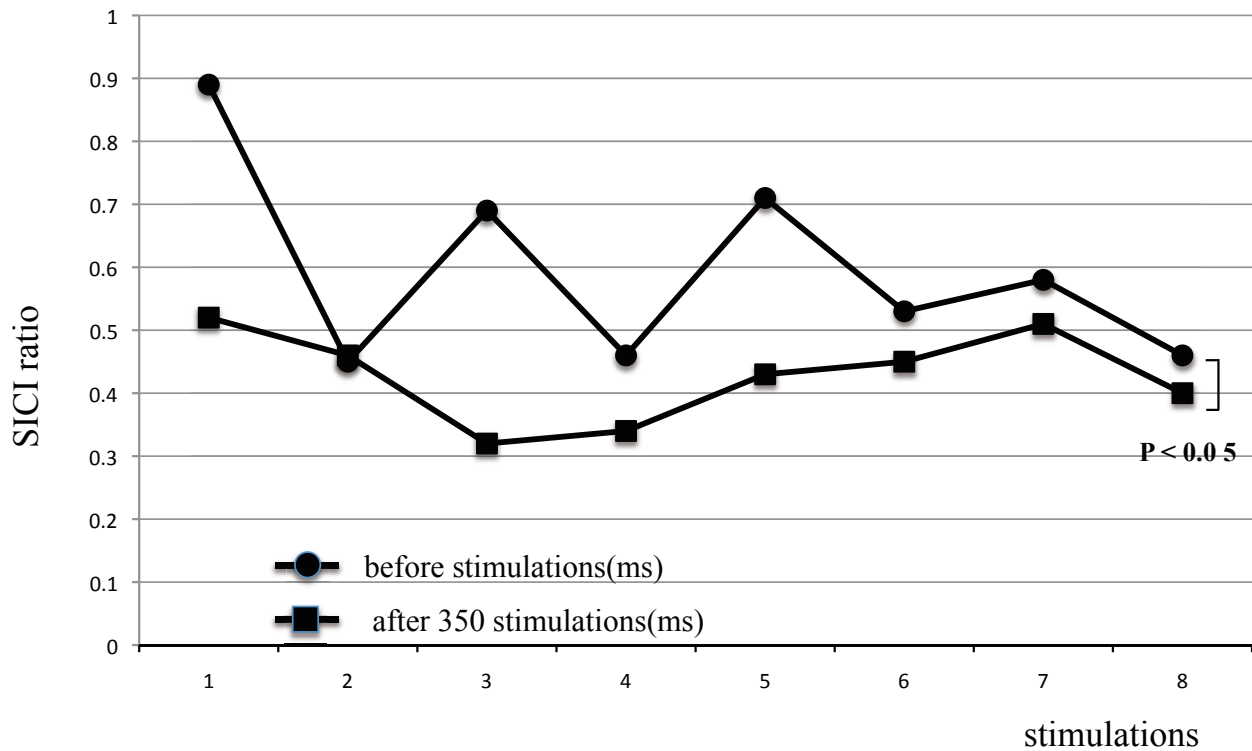


Fig. 6 Changes in SICI ratio before rTMS and after 350 stimulations. Eight sessions were conducted, and significant decreases were seen after 350 stimulations compared to those before rTMS.

with changes in oxy-Hb and oxy-Hb reflects brain activity.

Differences in the relative levels of oxy-Hb in finger-bending and writing movements observed in our case may be due to differences in brain activity in each task. However, reduced brain activity associated with the task may reflect the simplicity of the task.

Along with the functional recovery of the upper arms and fingers after rTMS, decreased activity of the intracortical inhibitory neurons (observed as changes in CSP and SICI) and relative decreases in the oxy-Hb levels revealed by NIRS suggest immediate effects.

Disorders in performing movement tasks, such as finger-bending and writing, are the result of abnormal neural activities in the cerebrum, primarily the prefrontal cortex. rTMS (1 Hz, 1.2 times the motor threshold) in the motor cortex was able to suppress or regulate this abnormal neural activity. NIRS also suggested that the effect of rTMS in the motor cortex extended to sites that are distant from the motor cortex.

PET evaluations performed using the method proposed by Siebner *et al.* [14], after conducting 1 Hz rTMS in the premotor cortex for hand dystonia, reported decreased blood flow in the prefrontal cortex, motor cortex, putamen, and thalamus. These discussed the possibility of rTMS effects extending to sites that were distant from the stimulation site, with suppression occurring both at the stimulation site and in the peripheral areas; our results from NIRS were in line with these findings.

Long-term effects were evaluated with the number of rTMS stimulations needed for the improvement of hand separation movement and based on STEF.

Twenty-five rTMS sessions were conducted over one year and nine months. Sessions 1–4 showed only mild improvements in tremor and right finger separation

movement; however, significant improvements were seen from Session 5 onwards. The number of stimulations required for achieving sufficient improvements gradually decreased. STEF also showed mild improvements after the first and second rTMS sessions; however, Sessions 9–11 showed significant improvements even before rTMS stimulation. Besides, the improvements seen after rTMS were maintained over a long period of time.

We believe that this suggests a change in neuroplasticity.

Various stimulation sites for low-frequency rTMS against dystonia have been reported, including the motor, premotor, supplementary motor cortices, and the sensory area [8, 14–17]. Changing the stimulation site and stimulation intensity and conducting tests for site selection based on subjective symptoms result in subsequent treatment effects.

Selecting effective stimulation sites individually according to indications for rTMS in hand dystonia patients was reported to lead to effective treatment. In this context, improvements in the patient's own subjective symptoms and evaluations according to each rTMS site and NIRS-based evaluations will be helpful.

In conclusion, in this study, we have reported a case of hand dystonia whose functions were restored early by low-frequency, above-threshold rTMS that targeted the motor cortex. Changes in plasticity due to long-term rTMS were also suggested.

The state of neural activity of the entire cerebral cortex during movement tasks before and after rTMS treatment was indirectly observed using NIRS, suggesting that it may be useful for evaluating the treatment technique and understanding of the pathophysiology of dystonia.

ACKNOWLEDGMENTS

We are grateful to Yutaka Imai of Shimadzu Corporation for his close involvement in the installation and operation of NIRS in this study.

REFERENCES

- 1) Alexander GE, Crutcher MD. Functional architecture of basal ganglia circuits: neural substrates of parallel processing. *Trends Neurosci* 1990; 13: 266–271.
- 2) DeLong MR. Primate models of movement disorders of basal ganglia origin. *Trends Neurosci* 1990; 13: 281–285.
- 3) Mink JW. The basal ganglia: focused selection and inhibition of competing motor programs. *Prog Neurobiol* 1996; 50: 381–425.
- 4) Kaji R, Murase N, Urushihara R, Asanuma K. Sensory deficits in dystonia and their significance. *Adv Neurol* 2004; 94: 11–17.
- 5) Nambu A, Chiken S, Shashidharan P, Nishibayashi H, Ogura M, Kakishita K, *et al.* Reduced pallidal output causes dystonia. *Front Syst Neurosci* 2011; 5: 1–6.
- 6) Neychev VK, Gross RE, Lehericy S, Hess EJ, Jinnah HA. The functional neuroanatomy of dystonia. *Neurobiol Dis* 2011; 42: 185–201.
- 7) Chen CH, Fremont R, Arteaga-Bracho EE, Khodakhah K. Short latency cerebellar modulation of the basal ganglia. *Nat Neurosci* 2014; 17: 1767–1775.
- 8) Siebner HR, Tormos JM, Ceballos-Baumann AO, Auer C, Catela MD, Conrad B, Pascual-Leone A. Low-frequency repetitive transcranial magnetic stimulation of the motor cortex in writer's cramp. *Neurology* 1999; 52: 529–537.
- 9) Niehaus L, von Alt-Stutterheim K, Rörich S, Meyer BU. Abnormal postexcitatory and interhemispheric motor cortex inhibition in writer's cramp. *J Neurol* 2001; 248: 51–56.
- 10) Ridding MC, Sheean G, Rothwell JC, Inzelberg R, Kujirai T. Changes in the balance between motor cortical excitation and inhibition in focal, task specific dystonia. *J Neurol Neurosurg Psychiatry* 1995; 59: 493–498.
- 11) Furukawa T, Izumi SI, Toyokura M, Masakado Y. Effective of low-frequency repetitive transcranial magnetic stimulation in Parkinson's disease. *Tokai J of Exp and Clin Med* 2009; 34: 63–71.
- 12) Arias P, Vivas J, Grieve KL, Cudeiro J. Controlled Trial on the Effect of 10 Days Low-Frequency Repetitive Transcranial Magnetic Stimulation (rTMS) on Motor Signs in Parkinson's disease. *Mov Disord* 2010; 25: 1830–1838.
- 13) Klein E, Kreinin I, Chistyakov A, Koren D, Mecz L, Marmur S, *et al.* Therapeutic efficacy of right prefrontal slow repetitive transcranial magnetic stimulation in major depression: a double-blind controlled study. *Arch Gen Psychiatry* 1999; 56: 315–320.
- 14) Siebner HR, Filipovic SR, Rowe JB, Cordivaric C, Gerschlagel W, Rothwell JC, *et al.* Patients with focal arm dystonia have increased sensitivity to slow-frequency repetitive TMS of the dorsal premotor cortex. *Brain* 2003; 126: 2710–2725.
- 15) Lefaucheur JP, Fénelon G, Ménard-Lefaucheur I, Wendling S, Nguyen JP. Low-frequency repetitive TMS of premotor cortex can reduce painful axial spasms in generalized secondary dystonia: a pilot study of three patients. *secondary dystonia: a pilot study of three patients. Neurophysiol Clin* 2004; 34: 141–145.
- 16) Murase N, Rothwell JC, Kaji R, Urushihara R, Nakamura K, Murayama N, *et al.* Subthreshold low-frequency repetitive transcranial magnetic stimulation over the premotor cortex modulates writer's cramp. *Brain* 2005; 128: 104–155.
- 17) Havrankova P, Jech R, Walker ND, Operto G, Tauchmanova J, Vymazal J, *et al.* Repetitive TMS of the somatosensory cortex improves writer's cramp and enhances cortical activity. *Neuro Endocrinol Lett.* 2010; 31(1): 73–86.
- 18) Kujirai T, Caramia MD, Rothwell JC, Day BL, Thompson PD, Ferbert A, *et al.* Corticocortical inhibition in human motor cortex. *J Physiol* 1993; 471: 501–509.
- 19) Kaneko T, Muraki T: Development and standardization of hand function test. *Bull Allied Med Sci (Kobe)* 1990; 6: 49–54.